

A QUALITATIVE AND QUANTITATIVE ELECTRON MICROSCOPIC STUDY OF THE NEURONS IN THE PRIMATE MOTOR AND SOMATIC SENSORY CORTICES

By J. J. SLOPER[†], R. W. HIORNS[‡] AND T. P. S. POWELL^{†§}

[†] *Department of Human Anatomy, University of Oxford,
South Parks Road, Oxford OX1 3QX, U.K.*

[‡] *Department of Biomathematics, University of Oxford,
Pusey Street, Oxford, OX1 2LA, U.K.*

(Communicated by C. G. Phillips, F.R.S. – Received 20 October 1977)

[Plates 1–9]

CONTENTS

	PAGE
INTRODUCTION	142
MATERIAL AND METHODS	143
RESULTS	144
(a) Qualitative study of the motor cortex	144
(i) Pyramidal cells	144
(ii) Betz cells	144
(iii) Large stellate cells	145
(iv) Small stellate cells	146
(v) Martinotti cells	147
(b) Qualitative study of area 3 <i>b</i> of somatic sensory cortex	148
(c) Quantitative study of motor cortex and area 3 <i>b</i> of somatic sensory cortex	148
(i) Pre-classification analysis	149
(ii) Results classified by cell type	153
DISCUSSION	162
REFERENCES	170

A study has been made of the neuronal somata in the motor and somatic sensory cortices of the monkey. Pyramidal cells in the motor cortex are very similar to those described previously in sensory and parietal cortical areas. The largest pyramidal cells in area 4, the Betz cells of layer V, are up to 50 μm in transverse diameter. Although basically resembling smaller pyramidal cells, the nucleus of a Betz cell often has a complex indentation and is smaller in relation to the overall size of the cell soma than is that of a smaller pyramid and the cytoplasm of Betz cells contains discrete clumps of endoplasmic reticulum. As with other pyramidal cells, the synapses on to Betz cell somata are all of the symmetrical type. Previous descriptions of stellate cells have been of cells receiving a high density of axosomatic synapses of

§ Elected F.R.S. 16 March 1978.

16-2

both the asymmetric and symmetrical type. Cells like this are found in both the motor and somatic sensory cortices and have been termed here large stellate cells. In addition to their high density of axosomatic synapses, they have abundant cytoplasm full of organelles and usually contain stacks of endoplasmic reticulum. Their dendrites similarly receive a high density of asymmetric and symmetrical synapses and contain prominent organelles and have a moderately varicose shape. Large stellate cells occur predominantly in layer IV in area *3b* but in the motor cortex they are also found commonly in the lower part of layer III and the upper part of layer V.

A third class of neuron has been described in both the motor and somatic sensory cortices and cells of this type have been termed small stellate cells. These receive a low density of axosomatic synapses, but some of these are of the asymmetric type and they have sparse cytoplasm with few organelles. They have a small rounded or fusiform soma, frequently have a dark nucleus, have no apical dendrite and their axon initial segments are thin and may be directed towards the cortical surface. Most of the rounded small stellate cells occur in layer II whereas those with fusiform somata occur more in the deeper layers of the cortex.

A quantitative study was made of the cells in a strip of the same width running through the full depth of the cortex in both cortical areas. The absolute numbers of cells in the strips of the motor and somatic sensory cortices were very similar as were the proportions of each type of neuron, 72% in each area being pyramidal with 21% being small stellate and 7% large stellate in the motor cortex, and 23% small stellate and 5% large stellate in area *3b*. The quantitative study also provided evidence that large and small stellate cells form two distinct populations rather than being a continuum.

INTRODUCTION

The neuron is the basic unit of nervous tissue and so a knowledge of the different types of cell present in an area of brain and of their distribution within that area is essential for a full understanding of its functioning. Our present histological knowledge of the populations of neurons in the neocortex depends on three main methods – the Golgi technique, the Nissl method and electron microscopy. Impregnation of a neuron by the Golgi technique can demonstrate the ramifications of its dendrites and axon and the shape of its soma and the neurons of the neocortex have been classified by a number of investigators on the basis of differences in these features (e.g. Cajal 1911; Lorente de N6 1949; Marin-Padilla 1969, 1970; Valverde 1971; Szent6gothai 1973; Jones 1975*b*). The division into pyramidal and stellate cell types is generally accepted and various sub-types of stellate cells have been described by the different authors. The Golgi technique, however, only demonstrates a small percentage of the cells present and so is of restricted use in determining their relative distributions and frequencies. In contrast the Nissl method stains all the cells present but only stains the cell somata. It can thus show the distribution of cell somata, and their sizes and shapes, and so forms the basis of architectonics, but is of little help in classifying cell types. Electron microscopy gives a detailed picture of the cell soma and the proximal parts of the dendrites and axons. However the more distal parts of these structures are not seen in continuity with the soma and so have to be identified by indirect methods. The neuronal somata of the neocortex have been studied qualitatively with the electron microscope (e.m.) by a number of authors (Colonnier 1968; Szent6gothai 1969; Jones & Powell 1970*a-c*; Lund & Lund 1970; Peters & Kaiserman-Abramof 1970; Garey 1971; Peters 1971; Cragg 1976) and pyramidal cells have been extensively described. In sensory and parietal areas criteria for distinguishing stellate or non-pyramidal cells from pyramidal cells have been determined and the description

of 'typical' stellate cells given by various of these authors are in general agreement; apart from a preliminary report of the present findings (Sloper 1973*a*), different types of stellate cells have not been distinguished using the electron microscope.

In this study a large number of cells from the motor cortex were studied qualitatively with the electron microscope. This showed typical pyramidal and stellate cells to be present, but there was a considerable proportion of neurons which could not be classified as pyramidal or 'typical' stellate cells. Because of the inevitably selective nature of this approach, a quantitative electron microscope study was then performed to try to confirm that these unclassifiable cells were a separate population and to study the relative proportions and distributions of the different cell types in the motor cortex.

The motor cortex has been classified as agranular cortex using the Nissl method and has been thought to consist predominantly of pyramidal cells. Area 3*b* of the somatic sensory cortex is a primary sensory projection area and is granular cortex which is considered on the basis of light microscopy to consist predominantly of stellate cells. It was therefore thought to be of interest to compare the neuronal populations of these two cortical areas to see what differences, if any, underlie their different functional and architectonic characters.

MATERIAL AND METHODS

All material was taken from the motor cortex (area 4 of Brodmann) and area 3*b* of the somatic sensory cortex of 21 young adult rhesus monkeys. Full details of the methods of fixation and processing are given in the previous paper (Sloper & Powell 1979*a*). The quantitative study comparing the neurons of the motor cortex and area 3*b* was done in one block taken from each area at the same medio-lateral position along the central sulcus of one hemisphere to minimize any possible artefactual differences between the appearances of the two areas. 'Thick' sections for light microscopy were cut from these blocks for determination of the cortical layers; sections were cut which were accurately perpendicular to the cortical surface and parallel to the 'grain' of the cortex by ensuring that these 'thick' sections contained long lengths of pyramidal apical dendrites. A strip of equal width running through the full depth of the cortex was taken from both areas, requiring three sections in the motor cortex and two in area 3*b*; the position of every cell fulfilling the criteria defined below was recorded on a map using the technique of Alksne, Blackstad, Walberg & White (1966) and each of these cells was photographed and its synapses studied at higher magnification. The criteria used were:

- (1) Every cell must receive at least one synapse on the section studied.
- (2) The nuclear membrane must not show nuclear pores face on (i.e. as circles) except at indentations. This excluded cells that were not sectioned approximately through the centre of the nucleus.
- (3) The cell must be completely within the strip of cortex being studied.

The strip of motor cortex contained 107 cells fulfilling the above criteria and that of area 3*b* contained 110 cells. Photographic prints were made at a standard magnification and the 14 parameters tabulated in the correlation matrix (figure 29) were determined from these for each cell. The mean diameter of a cell was measured as the mean of the greatest and least of diameters for a round or oval cell; for a cell with an apical dendrite it was taken as the mean of the transverse diameter and the height of the cell taken to the level where the outline of

the cell changed from convex to concave. The presence or absence of an apical dendrite was recorded as was the total number of dendrites arising from the soma. The synapses on the soma were counted, excluding any on lengths of dendrite arising from the cell; asymmetric synapses were identified only if one or more synapses clearly identifiable as being asymmetric were present. Nuclear indentations were recorded as being absent, single or multiple and a nucleus was classified as 'dark' if it contained dense chromatin as in figure 14, plate 6. The presence of one or more stacks of at least four cisternae of endoplasmic reticulum was considered as a positive and finally the general impression of whether the cell cytoplasm merged visually with the background neuropil or not was noted. The cells were then classified according to the criteria described for the different types in the first part of the results. The correlation matrix was done on an ICL 1906A computer.

RESULTS

(a) *Qualitative study of the motor cortex*

Pyramidal and stellate cells which resemble closely those which have been described in other cortical areas may be recognized in the motor cortex of the monkey. A proportion of cells was found which had features differing from previous descriptions; these have been termed small stellate cells, while those non-pyramidal cells which correspond broadly to previous descriptions have been called large stellate cells. Although size is by no means the most important distinguishing feature, these terms have been used because they are comparatively non-committal.

(i) *Pyramidal cells*

The somata, dendrites and axon initial segment of small pyramidal cells of the monkey motor cortex resemble closely those of small pyramidal cells described in other areas of the neocortex. There is, however, a greater proportion of larger pyramidal cells in the motor cortex of which the largest are the Betz cells. The soma of a pyramid is typically triangular in shape and often gives rise to one or more dendrites in a section (figure 1, plate 1). The nucleus is pale, of even density and may have a single or a more complex indentation and the cytoplasm contains a moderate number of organelles and cisternae of endoplasmic reticulum, these features becoming more prominent in the larger cells. The soma and proximal dendrites receive a small number of exclusively symmetrical synapses. The initial segments of these cells are directed towards the white matter and may have spines which receive synapses. In a number of examples the initial segment has been shown to give rise to a myelinated axon of similar diameter to itself.

(ii) *Betz cells*

Betz cells are the characteristic feature of the motor cortex and have been described in the cat (Kaiserman-Abramof & Peters 1972). In the monkey, Betz cells occur singly or in clusters in layer V of the motor cortex (figure 2, plate 2) and are up to 50 μm in transverse diameter. Although they are basically the same as other pyramidal cells, certain features become more prominent with the larger size of the cells. The nucleus of a Betz cell is small in relation to its cytoplasm and the nuclear membrane often shows a region of complex indentation (figure 4, plate 3). The nucleolus is large, may exceed 5 μm in diameter and has a well developed

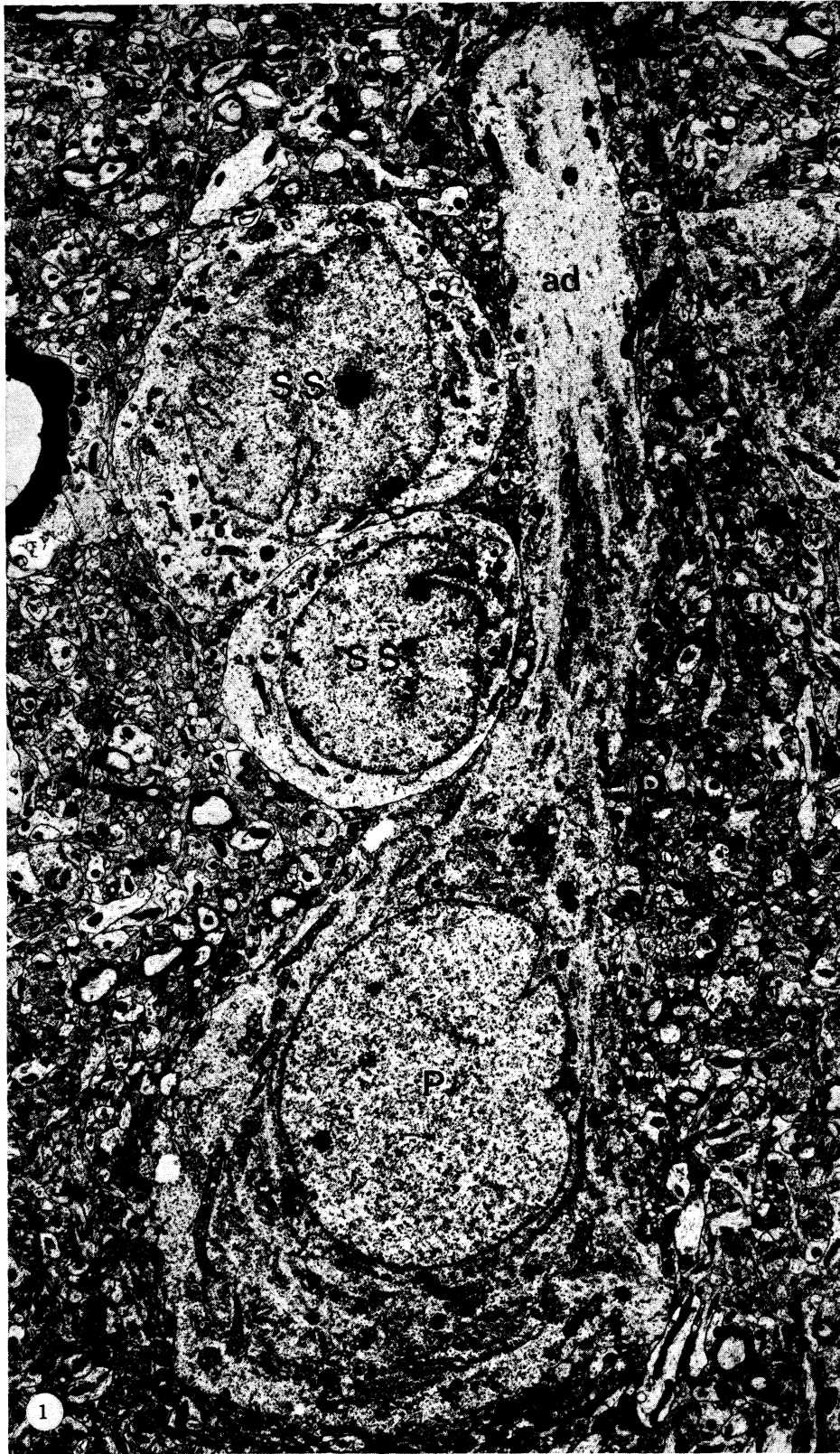

FIGURE 1. A pyramidal (P) and two small stellate neurons (SS) from layer II of the motor cortex. Note the more darkly staining nuclei with clumped chromatin of the small stellate cells and their paler cytoplasm containing few organelles. ad, Apical dendrite. (Magn. $\times 4500$.)

DESCRIPTION OF PLATE 2

FIGURE 2. A Betz cell from layer V of the motor cortex. Note the pyramidal shape and apical dendrite (ad), the indented nucleus (n) which is small in relation to the large amount of cytoplasm, and the clusters of endoplasmic reticulum (er). (Magn. $\times 2600$.)

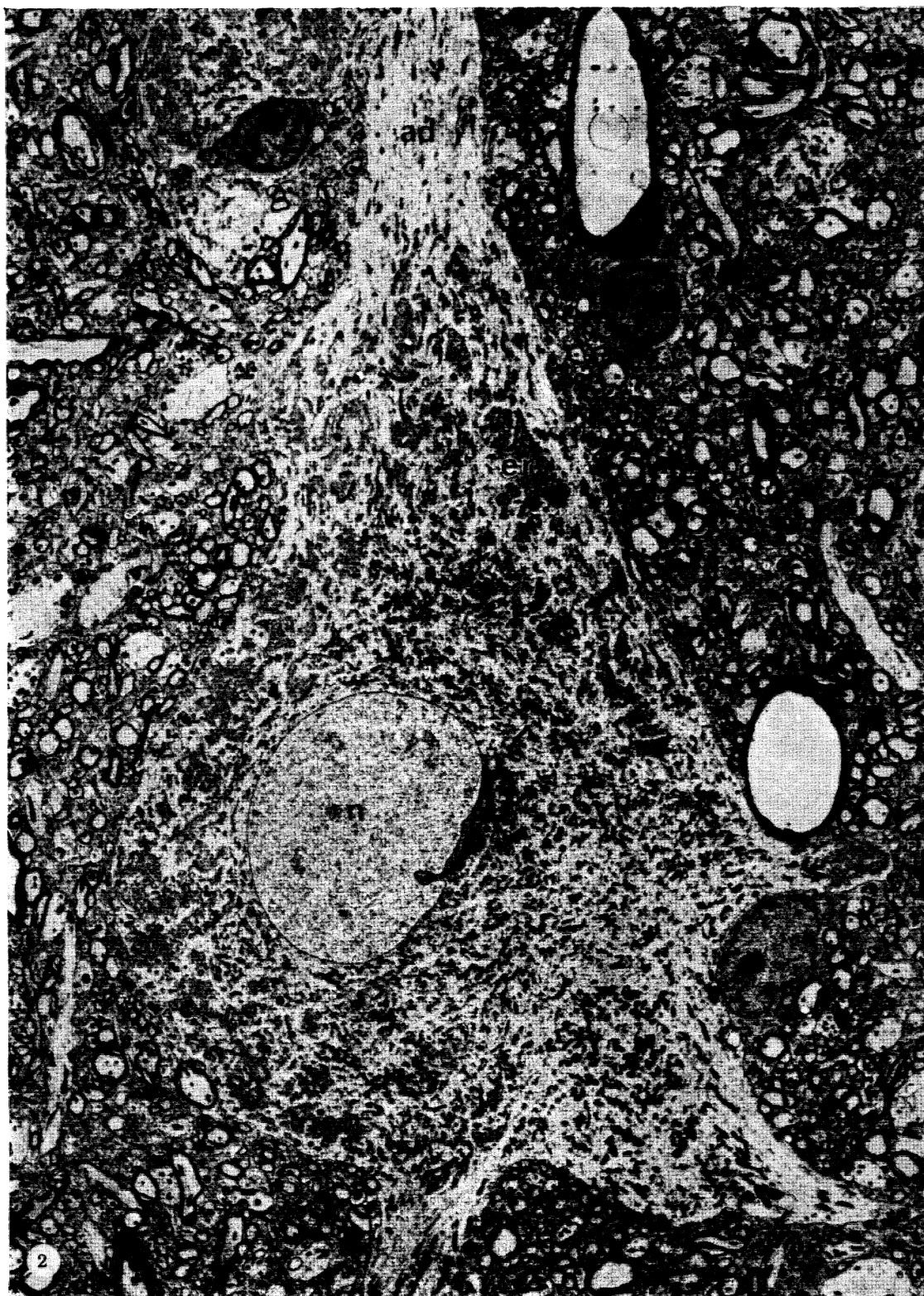
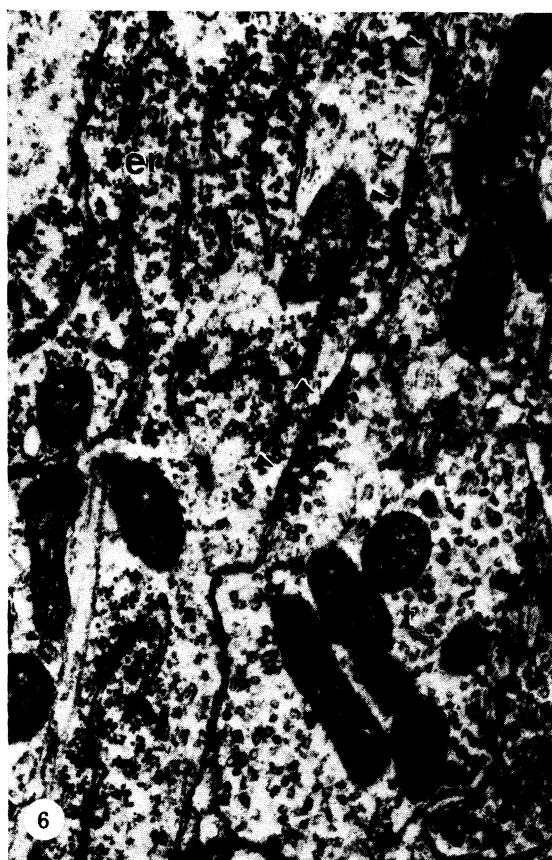
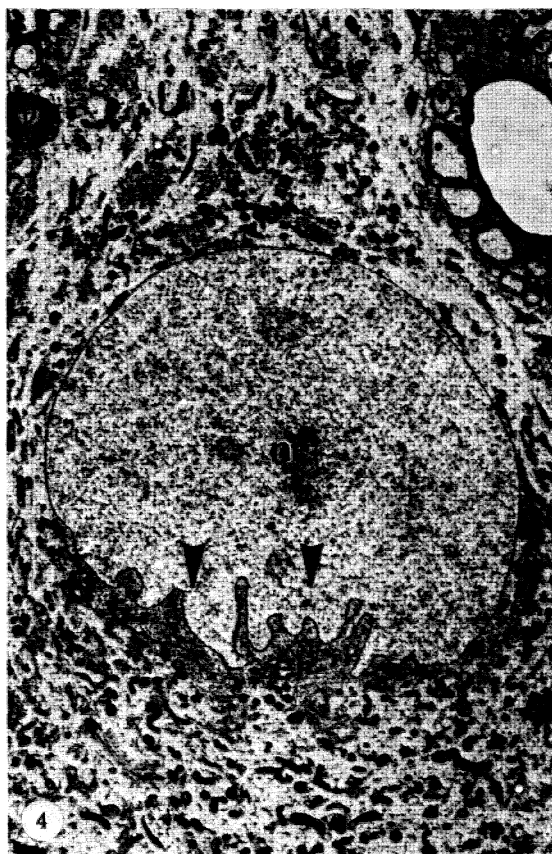
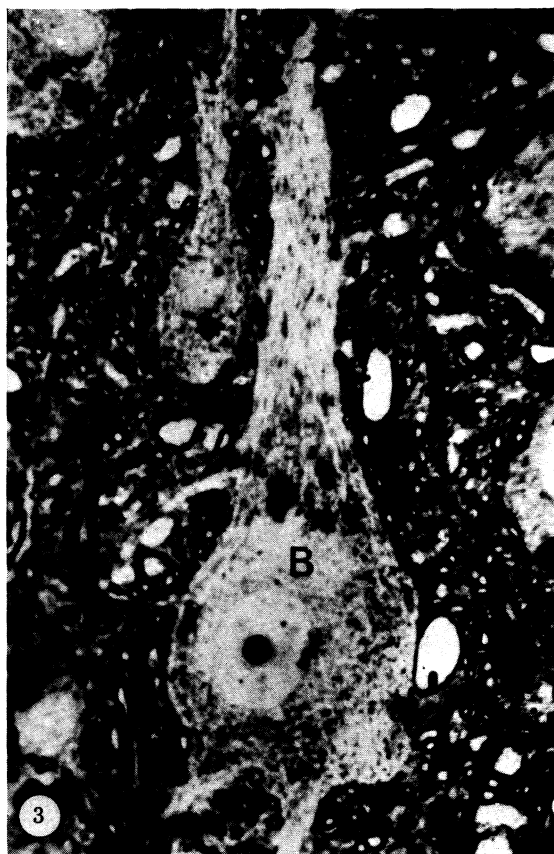


FIGURE 2. For description see opposite.



FIGURES 3-6. For description see opposite.

internal structure. The cell soma is often more markedly pyramidal in shape than that of a small pyramid because the diameter of the apical dendrite is larger in proportion to the diameter of the cell soma. There is a considerable amount of endoplasmic reticulum arranged in definite clumps with clear areas of cytoplasm between them (figure 5) and there is usually a cluster of endoplasmic reticulum in relation to an area of nuclear indentations (figure 4). The background cytoplasm of a Betz cell is light and when seen in close proximity to that of a large stellate cell it is clearly paler and the endoplasmic reticulum and ribosomes stand out more strongly against it. Numerous mitochondria are present and often small black membrane bound bodies are also present (figure 5). The soma generally receives up to six synapses; these are all of the symmetrical type (figure 6) and may be related to subsurface cisternae as in other pyramidal cells (Sloper 1973*c*; Sloper & Powell 1979*a*). The cell body and apical dendrite may give rise to spines which receive synapses and the same axon terminal may make a synapse on to the dendritic shaft or cell soma as well as on to a somatic spine. Many of the features described above may be seen with the light microscope using Araldite-embedded 'thick' sections; figure 3 shows a Betz cell in such a section.

The dendrites of Betz cells are generally parallel sided, may contain characteristic clumps of endoplasmic reticulum and usually receive few synapses; one Betz cell was found which gave off two small side branches from its apical dendrite and these received a considerable density of synapses. The axon initial segments of Betz cells are of large diameter, in some examples exceeding 5 μm . Because of their large size the membrane undercoating and bundles of neurotubules are less prominent than in smaller cells.

(iii) *Large stellate cells*

The neurons described here as large stellate cells correspond broadly to the stellate or non-pyramidal neurons described in other areas of the neocortex. The most obvious feature of cells of this type is the high density of synapses which they receive (figure 7, plate 4) and approximately 60% of these synapses are of the asymmetric type. The somata of the larger cells of this type in the motor cortex may receive 20 or more synapses in a single section; few receive less than five synapses. Serial sections have shown that this high density of synapses occurs consistently over the surface of these cells. The mean diameter of the soma is usually greater than 13 μm and may be as large as 30 μm . Its outline is generally rounded and it is unusual for more than one dendrite to be seen arising from the soma in any one section. The nucleus is often indented; the nucleolus is prominent and the different parts are well differentiated.

DESCRIPTION OF PLATE 3

FIGURE 3. The same Betz cell (B) as in figure 2 in a serial 'thick' section, stained with toluidine blue and seen under the light microscope. This Betz cell was initially found in the 'thick' section and serial thin sections were then cut to study it in detail. (Magn. $\times 850$.)

FIGURE 4. Details of the nucleus (n) of a Betz cell showing the characteristic complex nuclear indentations (large arrowheads) and their associated cisternae of endoplasmic reticulum (er). The apical dendrite of the Betz cell is towards the top of the picture. (Magn. $\times 3900$.)

FIGURE 5. Part of the cytoplasm of a Betz cell showing the characteristic clumps of endoplasmic reticulum and also mitochondria and dense bodies. (Magn. $\times 8400$.)

FIGURE 6. Part of the soma of a Betz cell which receives symmetrical axosomatic synapses (two arrowheads) from two pale axon terminals (t) which contain flattened vesicles. Note also the clumps of rough endoplasmic reticulum. (Magn. $\times 29000$.)

These cells have abundant cytoplasm which contains numerous prominent stacks of parallel cisternae of rough endoplasmic reticulum and frequent free ribosomes occurring both singly and in clusters; there is a high density of mitochondria, considerably more than in any of the other types of cell, and also frequent small electron-dense bodies.

Dendrites of large stellate cells are studded with asymmetric and symmetrical synapses (figure 7; figures 9 & 10, plate 5). They do not have a markedly varicose shape and tend to run in a straight line for a considerable distance; their origin from the cell soma does not show a marked constriction (figure 7). They contain prominent microtubules and a high concentration of organelles, particularly ribosomes and mitochondria, and occasionally give rise to spines (figure 9). Dendrites seen cut in isolation in the neuropil share the above features and have therefore been identified as being those of large stellate cells. The gap junctions which occur sparsely in the cortex are found predominantly on the dendrites and somata of this type of cell and would appear to be a particular feature of it (Sloper 1972).

The initial segments of large stellate cells resemble those of small pyramidal cells but may often be curved. They may arise either directly from the cell soma or from a dendrite at a point close to its origin from the soma (figure 8). They are often directed towards the cortical surface or obliquely, and in serial sections two of these initial segments were traced to the point where they gave rise to myelinated fibres of similar calibre to the initial segment.

Large stellate cells in the motor cortex occur mostly in a horizontal band from the lower part of layer III and including layers IV and V although the occasional example is found in the more superficial layers. The dendrites of the type identified as belonging to these cells occur in a somewhat wider band of cortex. Several cell somata of this type may be found in the same part of a section and examples are found close to pyramidal cells of similar diameter; the very large ones often seem to occur close to Betz cells. The appearance of cells of this type is remarkably consistent and they form a distinct population of cells within the cortex.

(iv) *Small stellate cells*

A considerable number of cells were found in the motor cortex which could not be classified as either of the types described previously. As they are of stellate rather than pyramidal type, they have been termed small stellate cells. They have small rounded or fusiform somata, most having a mean diameter of 9–12 μm . The somata receive few synapses, rarely more than three in a single section. Serial sections have shown that a cell of this type may often receive no synapses at all on a number of sections in a series through it and it may then be almost indistinguishable from a glial cell. The nucleus is frequently dark with rather granular chromatin that often occurs in dense clumps (figure 11, plate 6; figures 15 & 18, plate 7 and figure 19, plate 8) and the nuclear membrane may have complex indentations. The fusiform cells often have a rather angular nucleus and there is frequently a longitudinal nuclear indentation. The cytoplasm is sparse and in the rounded cells it has a very light background and contains very few organelles, although the Golgi apparatus is usually prominent. Often no dendrite is seen to arise from the soma in a given section and it is unusual to find more than two doing so. The origin of a dendrite from the cell soma is generally markedly constricted and may closely resemble that of an initial segment as there are often a few neurotubules aggregated in it (figure 14), but a definite initial segment may be found in addition (figure 19). These features differentiate small stellate cells from the large type and in single sections it is more difficult to

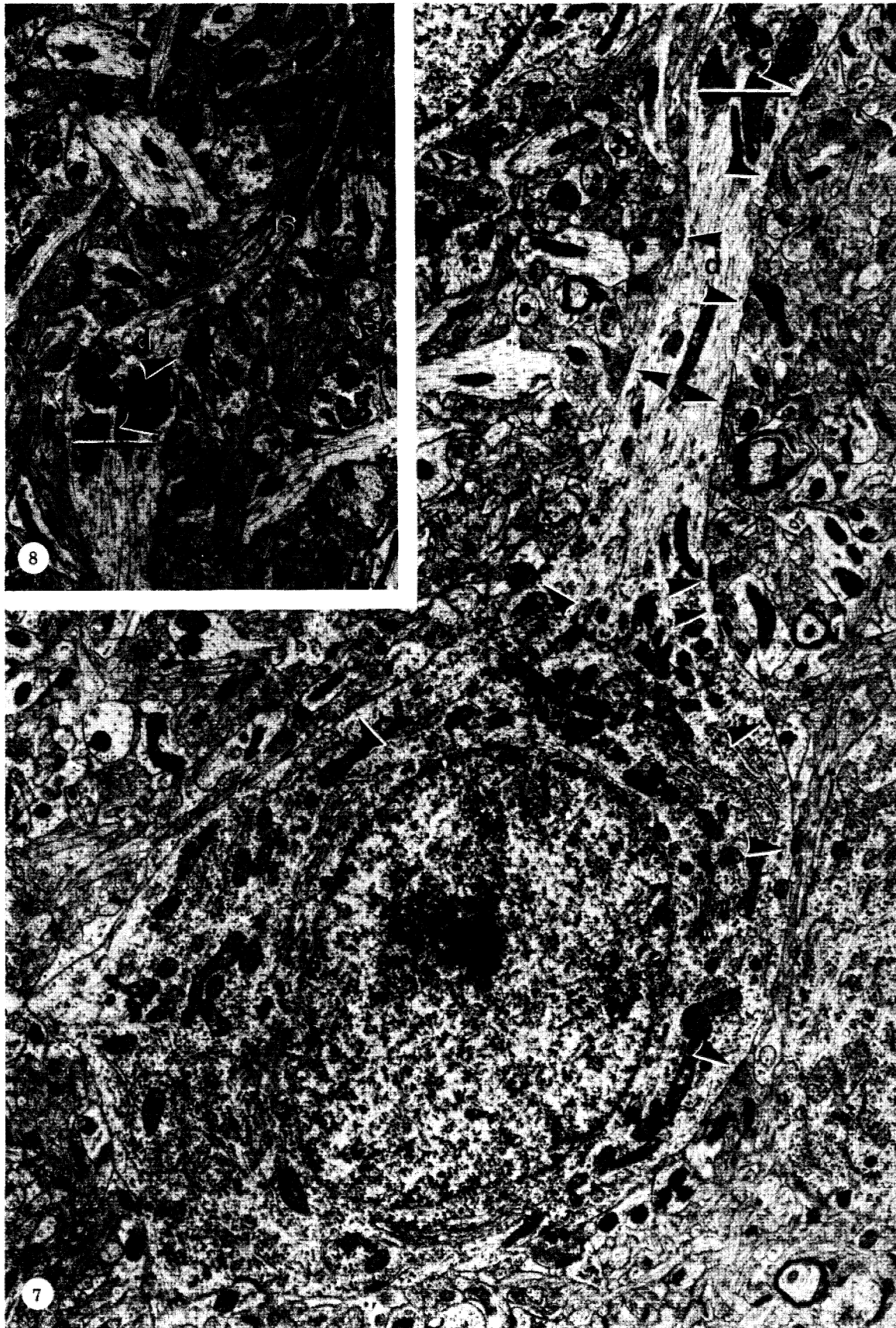


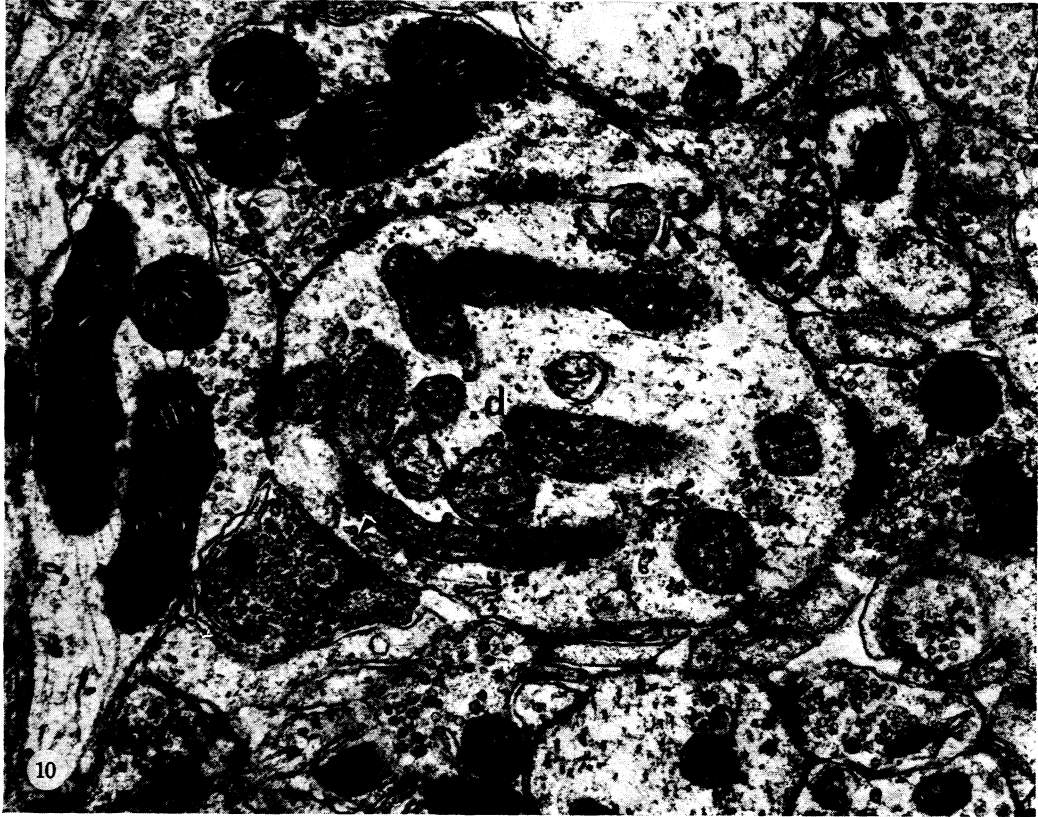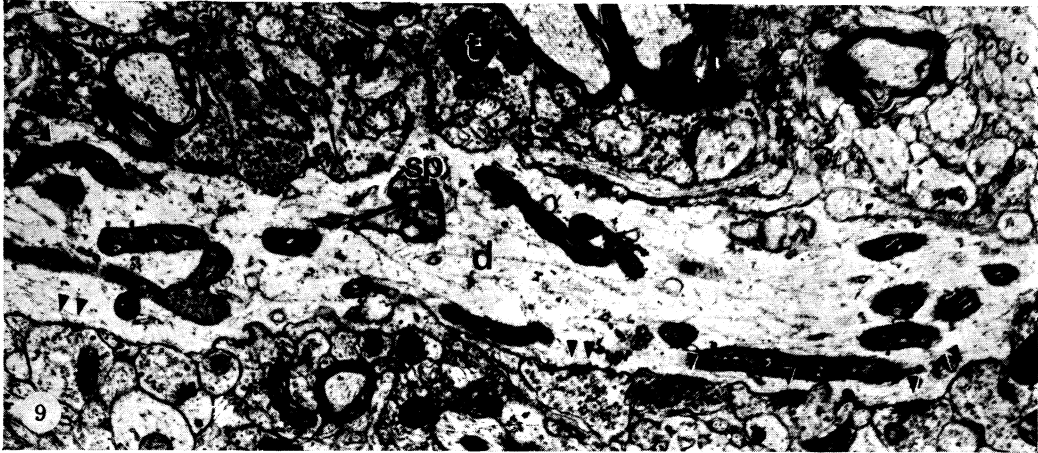
FIGURE 7. Large stellate neuron from layer III of the motor cortex. Note the abundant cytoplasm full of organelles. The cell soma and dendrite (d) receive a considerable number of synapses (large arrowheads) although not as many as in many examples. (Magn. $\times 11\,000$.)

FIGURE 8. The origin of the initial segment (is) of the large stellate cell of figure 7 from the continuation of its dendrite (d) in a close serial section. The black bar occupies an equivalent position on both of the illustrations. Note the curvature of the first part of the initial segment. (Magn. $\times 11\,000$.)

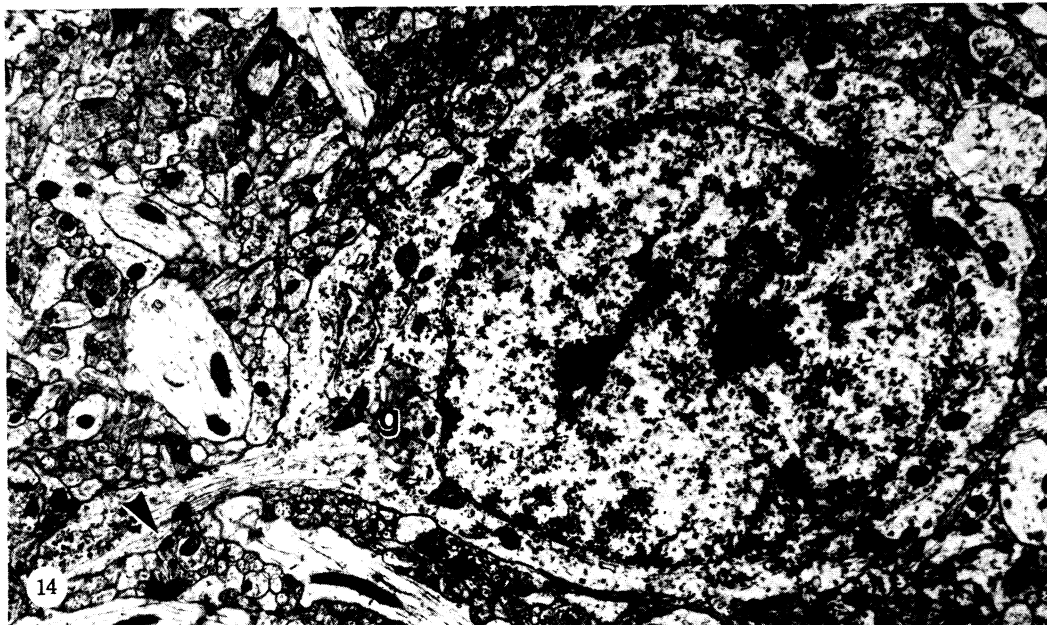
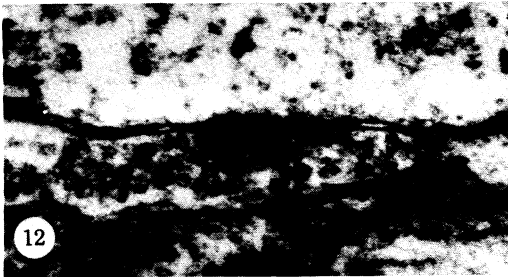
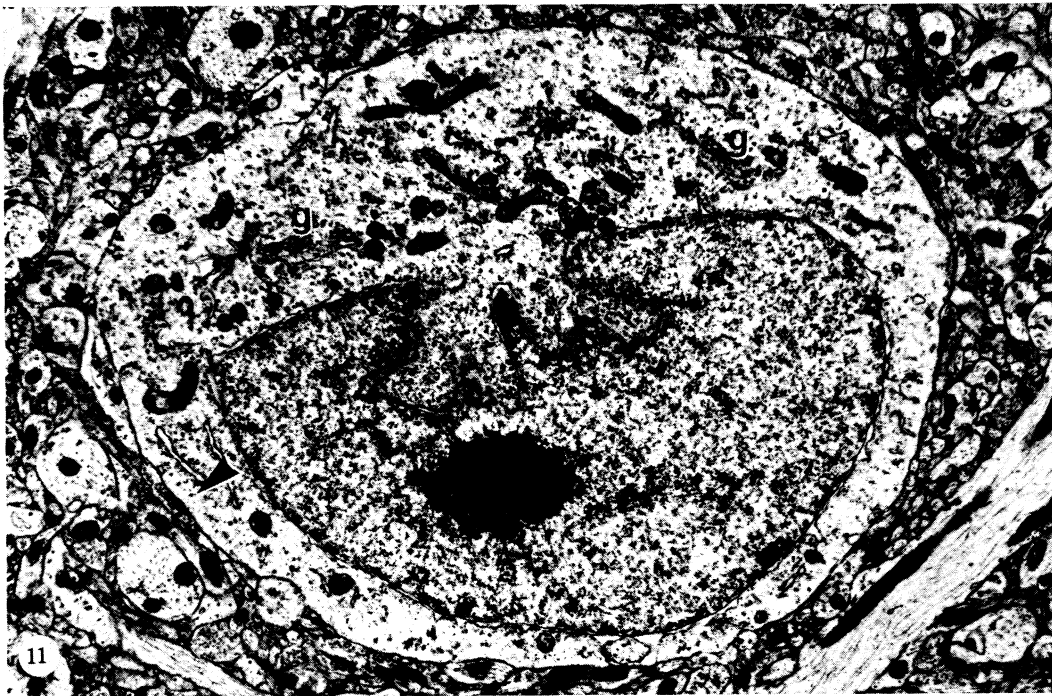
DESCRIPTION OF PLATE 5

FIGURE 9. The dendrite (d) of a large stellate cell from the motor cortex which is unusual in having a spine (sp). Note the large number of asymmetric synapses (single arrowheads) as well as symmetrical synapses (two arrowheads) received by the shaft of the dendrite and the high concentration of organelles in its cytoplasm. (Magn. $\times 14000$.)

FIGURE 10. Transverse section of a large stellate dendrite from layer IV of the somatic sensory cortex. Note the large number of synapses it receives, including a clearly asymmetric one (arrowhead) and the high density of mitochondria and ribosomes in its cytoplasm. (Magn. $\times 29000$.)



FIGURES 9 and 10. For description see opposite.



FIGURES 11-14. For description see opposite.

distinguish them from small pyramidal cells. However, a proportion of the synapses they receive are asymmetric (figures 12 and 17) and this has never been seen on the somata of definite pyramidal cells; the initial segment may be directed towards the surface of the cortex (figure 19), also not seen with undoubted pyramids with the possible exception of inverted pyramids in layer VI; and these cells have been shown not to have apical dendrites by studying serial sections taken through the soma.

Most of the rounded small stellate cells occur in layer II and occasional ones occur in layer I whereas the fusiform type is found more in the deeper layers of the cortex. The occasional dendrites seen arising from these cells tend to have a more varicose shape than those of large stellate cells but receive a lower density of synapses; a proportion of these synapses are of the asymmetric type. It is unusual to cut any length of dendrite in continuity because they usually turn out of the plane of the section after a short distance and in serial sections they may be seen to follow a tortuous course. The fusiform cells may however have a large polar dendrite which is not varicose in shape (figure 18). Because of the rarity with which lengths of dendrite are cut in continuity with small stellate somata it is difficult to define their characteristics, but the dendrites having a very varicose shape and light background cytoplasm and receiving a moderate number of synapses of both asymmetric and symmetrical types which are seen in isolation in the neuropil, probably arise from small stellate cells because they occur prominently in layer II where the majority of round small stellate cells are found.

The initial segments of small stellate cells are thin, usually about 0.5 μm in diameter, and are often directed towards the surface of the cortex (figures 19 and 20). They have the typical membrane undercoating and one or more bundles of neurotubules. It has not proved possible to follow these initial segments for any distance using serial sections, mainly because of their small size and variable orientation.

Small stellate cells do not appear to form one homogeneous population. The round and fusiform cells appear to be two distinct groups with differing features and laminar distributions and it seems likely that further study will confirm the presence of several sub-types of small stellate cells.

(v) *Martinotti cells*

In the deep part of layer V and in layer VI of the motor cortex a few neurons have been found which have axon initial segments directed towards the superficial layers of the cortex (figures 21, 22, plate 9). In general these cells are fairly large and often have a distinctly fusiform shape. They appear generally pale and contain a moderate number of organelles in their cytoplasm. The cell somata receive few synapses but more are found on large polar dendrites, some of which are of the asymmetric type. These cells are uncommon and do not

DESCRIPTION OF PLATE 6

FIGURES 11 AND 12. Round small stellate cell from layer II of the motor cortex which receives an asymmetric synapse (large arrowhead, lower left). This is shown at greater magnification in figure 12. Note the indented nucleus with darkly staining clumped chromatin and the pale cytoplasm with few organelles and prominent Golgi apparatus (g). (Magn., figure 11 \times 8400, figure 12 \times 29000.)

FIGURES 13 AND 14. Round small stellate cell from layer II of the somatic sensory cortex (area 3b) which receives an asymmetric synapse on its dendrite (large arrowhead). This is shown at greater magnification in figure 13. Note the darkly staining clumps of chromatin in its indented nucleus, its pale cytoplasm and its prominent Golgi apparatus (g). (Magn. figure 13 \times 29000, figure 14 \times 8400.)

fall into any of the groups described above. In view of their position in the deep layers of the cortex and their superficially directed axons, it is possible that these neurons correspond to the Martinotti cells of light microscopy (Cajal 1911).

(b) *Qualitative study of area 3b of somatic sensory cortex*

Pyramidal, large stellate and small stellate cell types could all be identified in area 3b of the somatic sensory cortex and in general their features are the same as in the motor cortex. The main differences from the motor cortex appear to be due to differences in the mean sizes of the cell types. There were fewer large pyramidal cells than in the motor cortex but, unlike the somatic sensory cortex of the cat (Jones & Powell 1970a), the somatic sensory cortex of the monkey contains a proportion of large pyramids which have definite clusters of endoplasmic reticulum in their cytoplasm. The large stellate cells in area 3b were also in general smaller than in the motor cortex and no very large examples were found. Small stellate cells (figures 13 and 14) were slightly smaller but there was considerably more overlap between the size ranges of the large and small stellate cells in the somatic sensory cortex than in the motor cortex. The laminar distributions of the different cell types were basically the same in both areas but large stellate cells appeared to be more confined to layer IV in area 3b, probably because of the greater thickness of this layer in the somatic sensory cortex than in the motor cortex.

(c) *Quantitative study of motor cortex and area 3b of somatic sensory cortex*

The results in this section are based on 107 cells from the motor cortex and 110 cells from area 3b of the somatic sensory cortex which were obtained from an equal width strip running through the full depth of the cortex and which fulfilled the criteria described under 'Material and methods'. The quantitative data from these cells were analysed in two stages. Before any classification of the cells was done a number of analyses were performed on the data relating to the whole sample of cells from each area (figures 23–29). This produced several pieces of evidence which were not in any way dependent on a previous classification of cells and gave independent support from an unselected sample of cells to the classification made above using the qualitative results. The cells in the study were then classified using the criteria described under the qualitative results to provide quantitative information about each class of cell and to make a detailed comparison of the characteristics, proportions and distributions of the

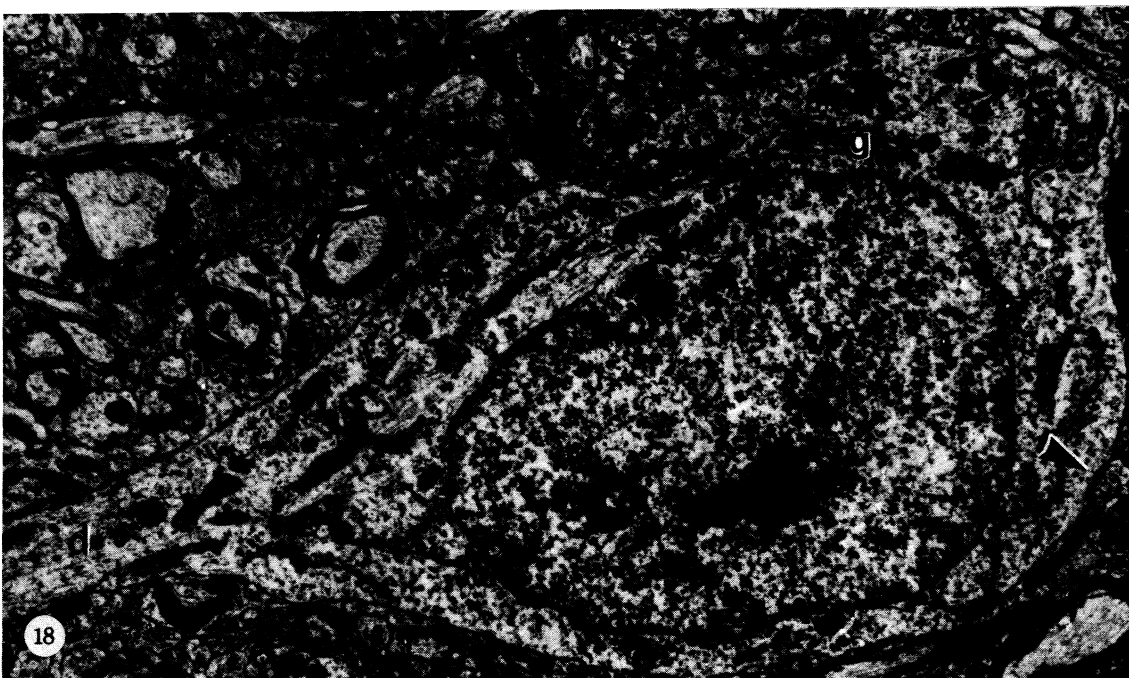
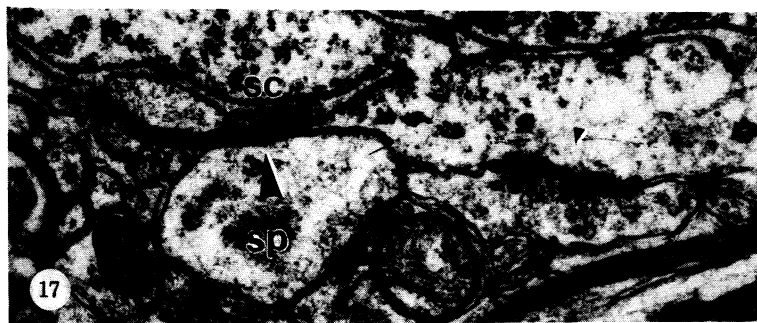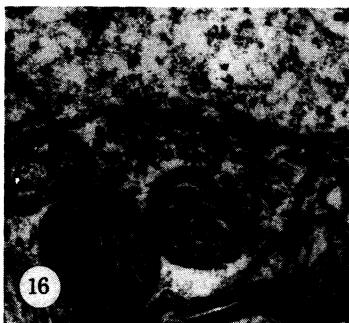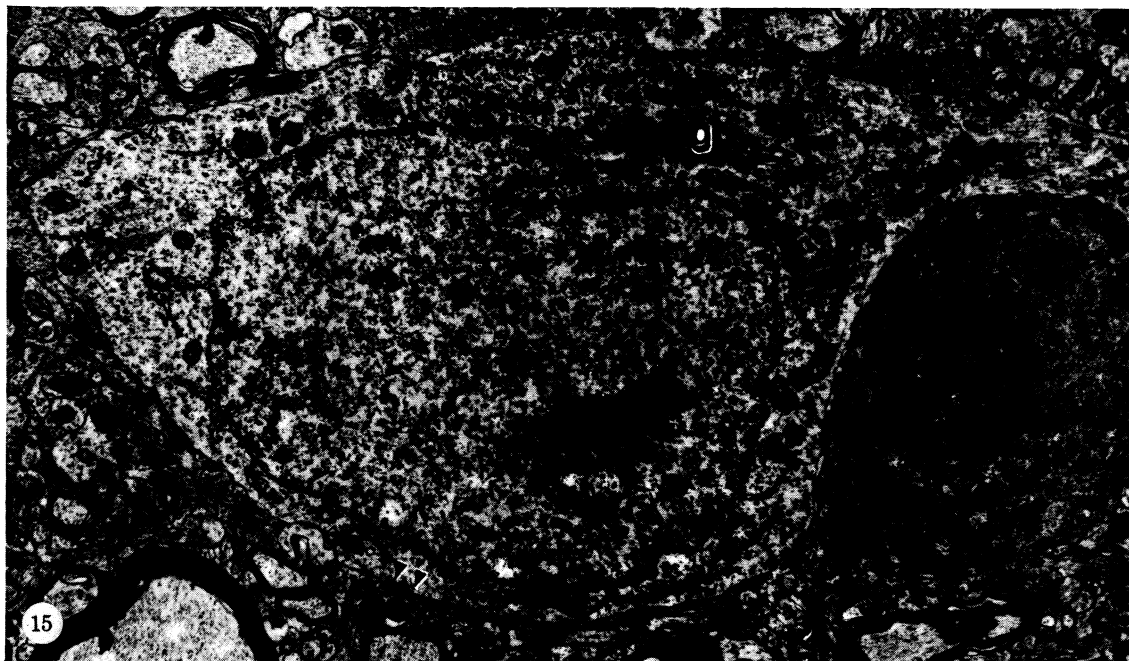
DESCRIPTION OF PLATE 7

FIGURE 15. Fusiform small stellate cell from layer V of motor cortex. Note the dark nucleus with clumped chromatin and the prominent Golgi apparatus (g). The cytoplasm is rather darker and has more organelles than a round small stellate cell, but the cell receives only one synapse in this section (two arrowheads). (Magn. $\times 9000$.)

FIGURE 16. Detail of the symmetrical synapse received by the neuron of figure 15. (Magn. $\times 40000$.)

FIGURE 17. Detail from a serial section of the same fusiform small stellate cell as figure 15, showing it receiving an asymmetric axosomatic synapse (small arrowhead). A symmetrical exposed membrane thickening (large arrowhead) on a spine (sp) is apposed to the plasma membrane of the neuron where it is related to a subsurface cistern (sc.). (Magn. $\times 40000$.)

FIGURE 18. The same fusiform small stellate cell as figure 15 but 20 serial sections away and showing a dendrite (d) arising from the opposite pole of the neuron. The neuron also receives a synapse in this section (large arrowhead) but in many of the sections of this series no synapse was present on this neuron. Note that the Golgi apparatus is still prominent. (Magn. $\times 9000$.)



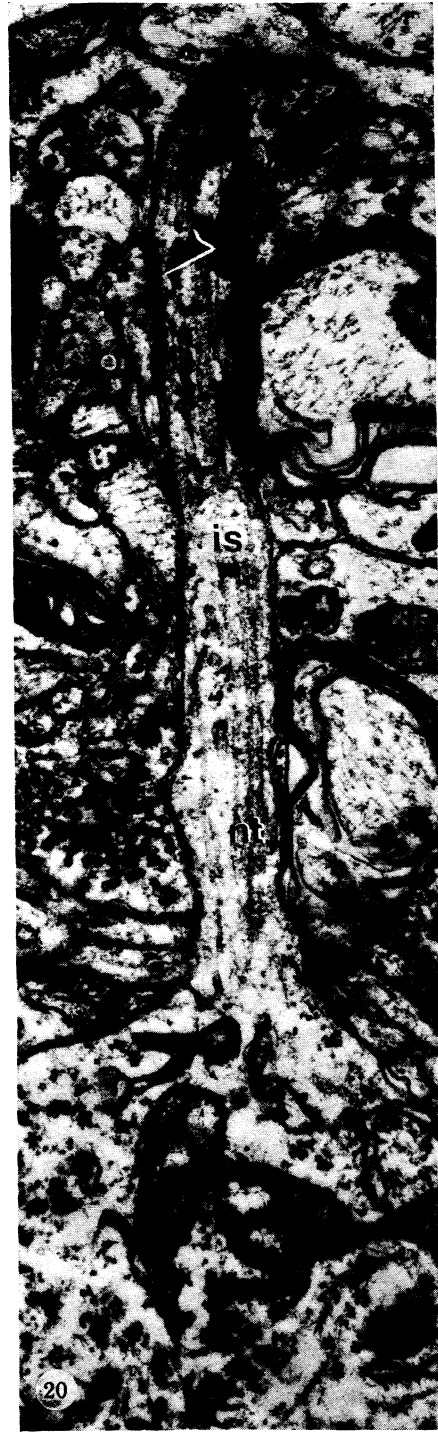
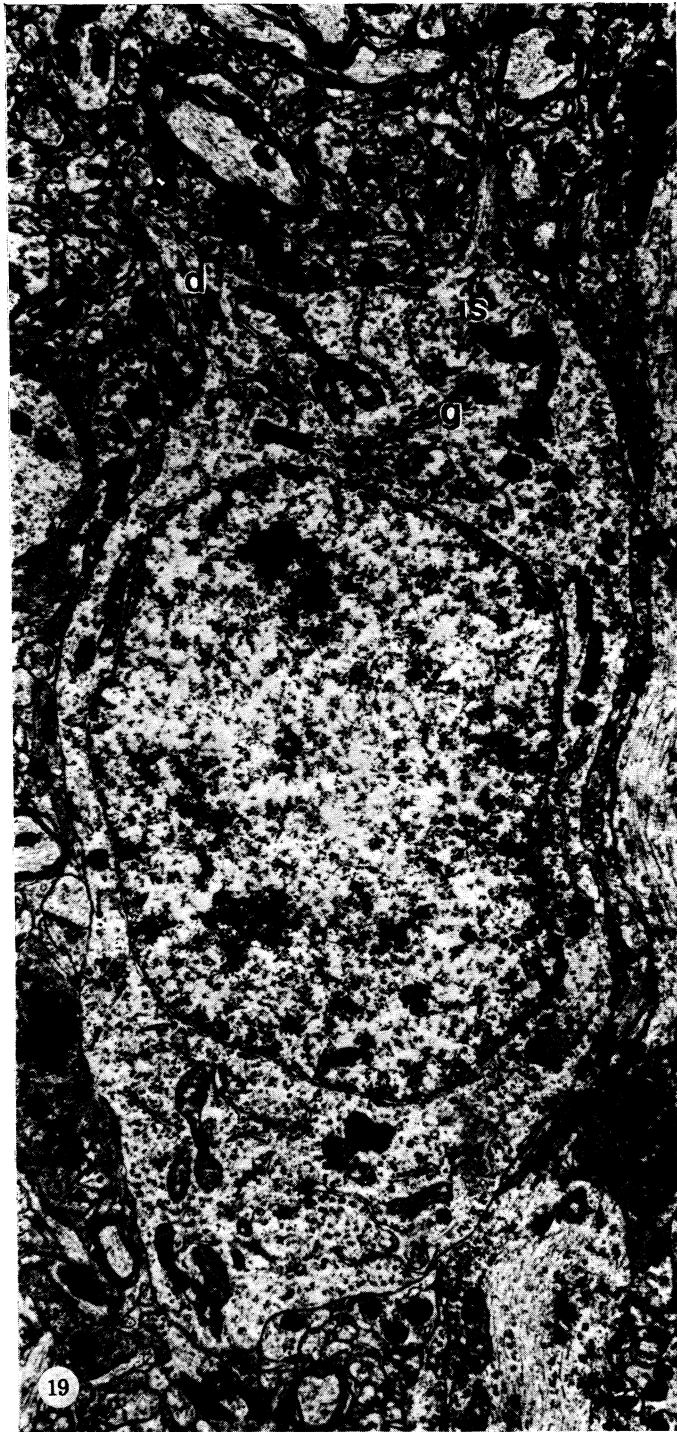FIGURES 15-18. For description see opposite.

(Facing p. 148)

DESCRIPTION OF PLATE 8

FIGURE 19. Small stellate cell from layer V of the motor cortex, showing the origin of its axon initial segment (is) which is directed towards the surface of the cortex. Note the rather similar appearance of the origin of the dendrite (d) and also the Golgi apparatus (g). (Magn. $\times 9000$.)

FIGURE 20. Greater magnification of the initial segment of the same cell as figure 19, five serial sections away. Note the typical bundle of neurotubules (nt) and membrane undercoating (arrowhead) in the initial segment and its small diameter. (Magn. $\times 31\,000$.)



FIGURES 19 and 20. For description see opposite.

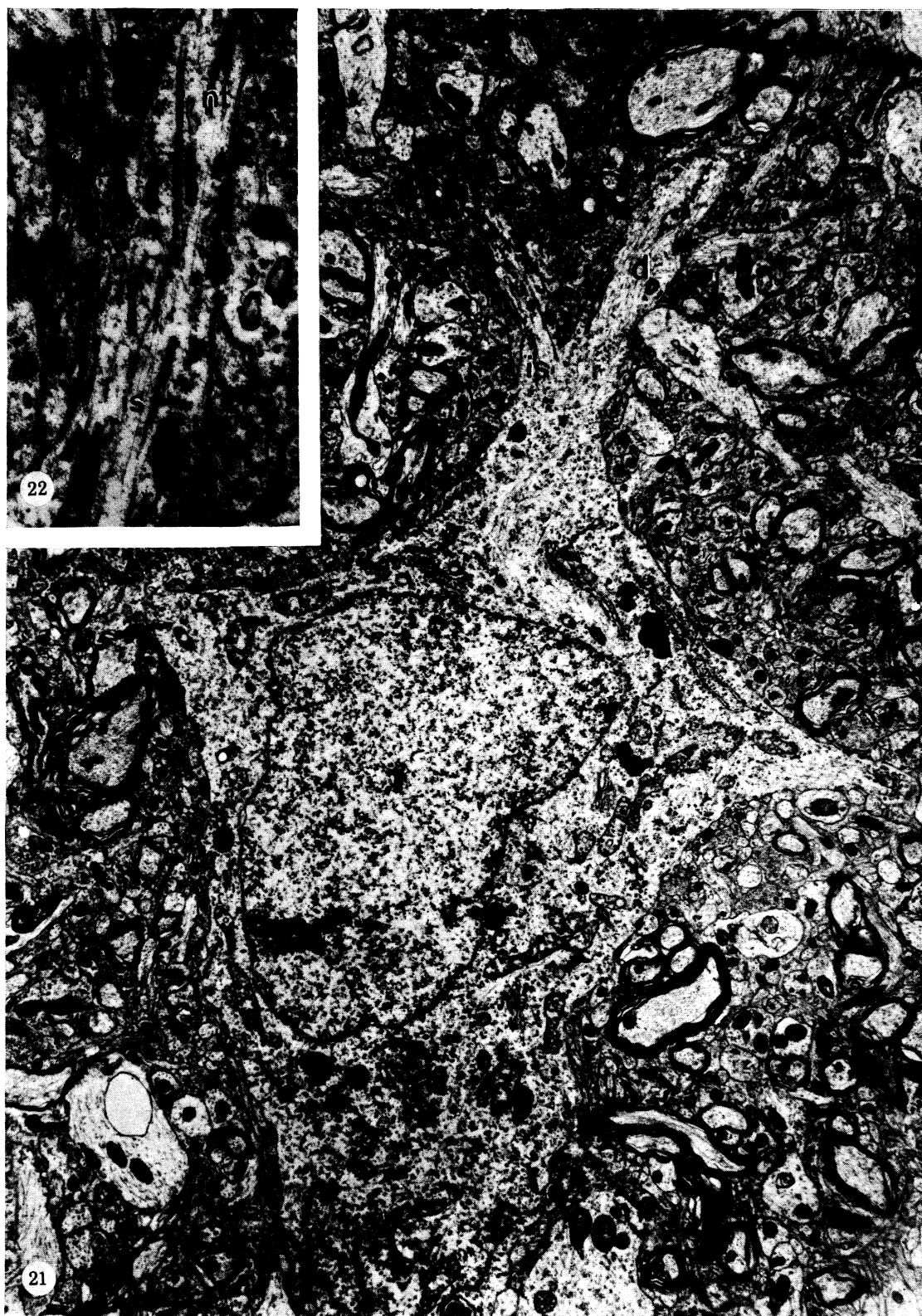


FIGURE 21. Neuron from layer V of the motor cortex. This is an example of an unusual type of neuron from layer V which is large, receives few synapses and has an axon initial segment (is) directed towards the cortical surface, and is therefore probably a Martinotti cell. The initial segment arises from the root of the dendrite (d). (Magn. $\times 6300$.)

FIGURE 22. Initial segment of the neuron of figure 21 at a greater magnification and in the next serial section. Note the bundle of neurotubules (nt). (Magn. $\times 19000$.)

cells in the two areas of cortex studied. A full account of the data obtained from each cell together with detailed analyses have been given elsewhere (Sloper 1977) and copies may be obtained from the authors.

(i) *Pre-classification analysis*

From histograms comparing the mean diameters of all the cells studied in the motor and somatic sensory cortices (figure 23), it can be seen that in the motor cortex the cells are in general rather larger and that they also have a wider range of mean diameters. In the motor cortex in particular there is a suggestion that the size distribution is bimodal; subsequent

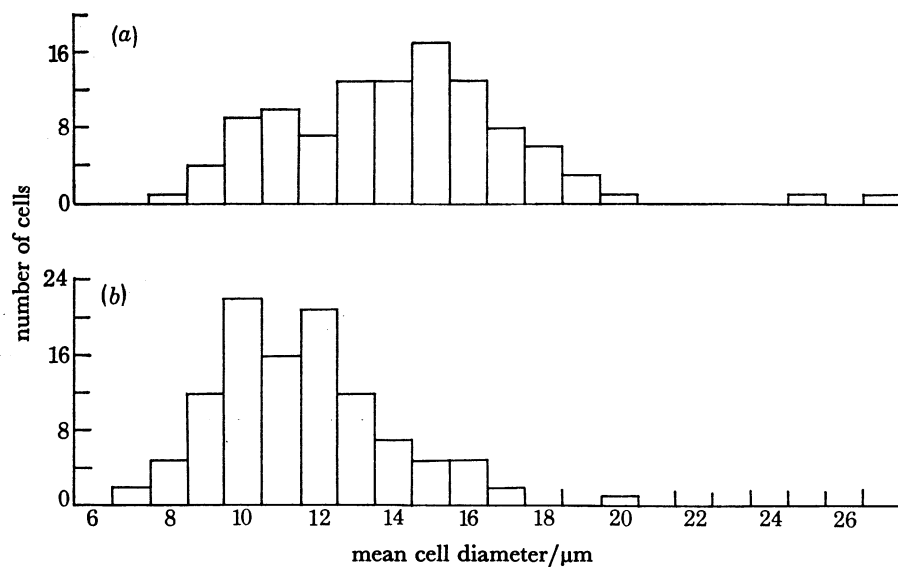


FIGURE 23. Histograms showing the distribution of mean cell diameters in (a) motor and (b) somatic sensory cortices (area 3b).

classification in fact showed that most of the cells in the peak below 12 μm diameter were small stellate cells and most of those above 12 μm were pyramids and large stellate cells. This was not as clearly shown in area 3b, possibly being blurred because of the smaller overall spread of size. The mean of the diameters of all cells in the motor cortex was 14.16 μm and in area 3b was 11.55 μm.

Figure 24 shows that about half (57%) of the cells in the motor cortex which are more than 13 μm in diameter have apical dendrites whereas only a few (13%) of those with a mean diameter of less than 13 μm have one. This strongly suggests that there is a population of cells present in the motor cortex of less than 13 μm mean diameter which does not have apical dendrites; on subsequent classification most of these cells, smaller than 13 μm and without an apical dendrite, were found to be small stellate cells. Figure 25 shows that there is similarly a marked reduction in the proportion of cells having apical dendrites below a mean diameter of about 11 μm in area 3b.

In histograms of the numbers of synapses found on each cell profile (figure 26) the most striking feature in both cortical areas is the remarkably small proportion of cells receiving the large numbers of synapses associated with 'typical' stellate cells. This suggests that this type of cell is rather less common than had been previously supposed. Neurons receiving no synapses

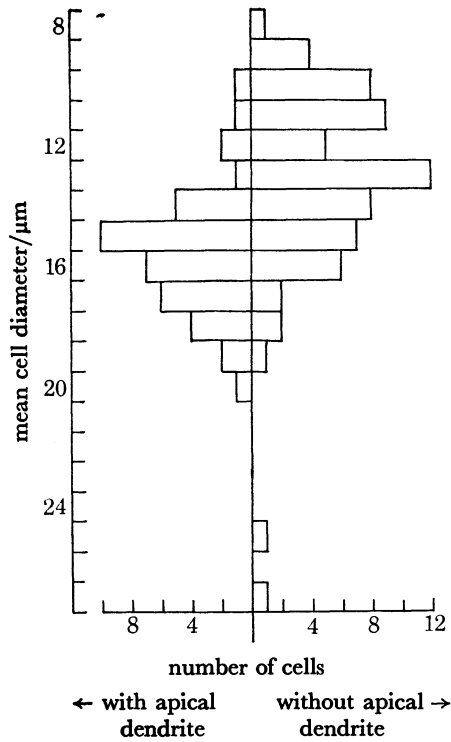


FIGURE 24

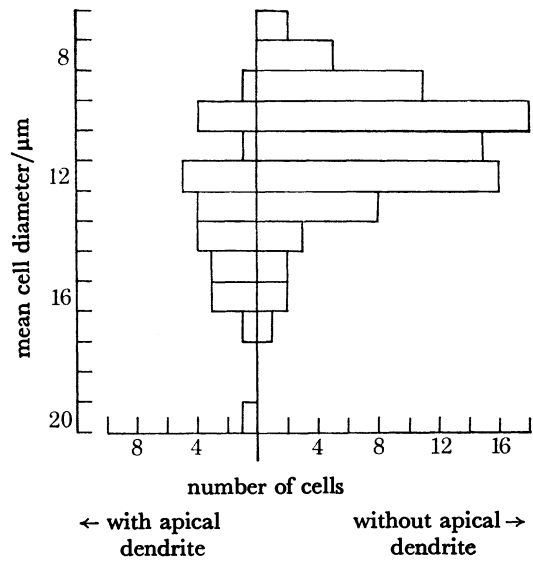


FIGURE 25

FIGURE 24. Histogram showing the size distribution of cells with and without apical dendrites in the motor cortex. Note the lack of small cells having apical dendrites.

FIGURE 25. Histogram of the size distribution of cells with and without apical dendrites in the somatic sensory cortex. Note that a smaller proportion of small neurons have apical dendrites compared to the larger neurons.

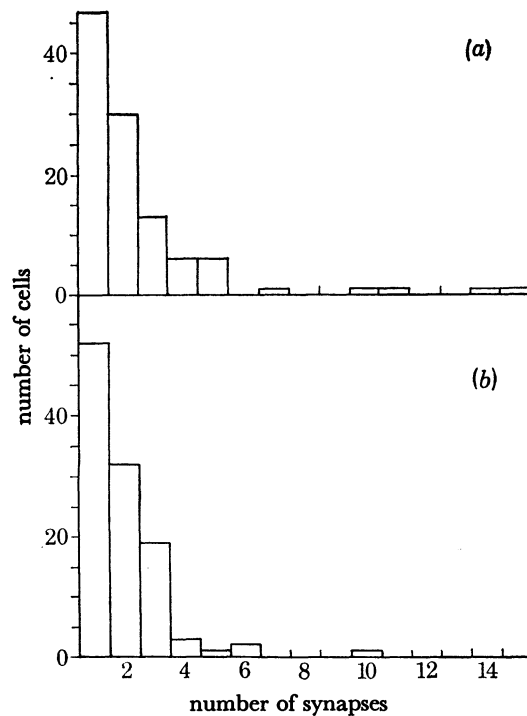


FIGURE 26. Histograms showing the distribution of the numbers of synapses found per cell profile in a single section in (a) motor and (b) somatic sensory cortices (area 3b). Note that only a small proportion of cells receive a large number of synapses in either area.

in the section studied were excluded by the criteria used, but a statistical estimate of their numbers is given under the individual cell types below.

To investigate the relationship between the diameter of a cell and the number of synapses it receives, the two parameters were plotted against each other for all the motor and somatic sensory cells (figures 27 and 28). The number at each point represents the number of cells

mean cell diameter																							
μm ...		7	8	9	10	11	12	13	14	15	16	17	18	19	20	21	22	23	24	25	26	27	28
number of synapses																							
17
16
15	1
14	1	.
13
12
11	1
10	1
9
8
7	1
6
5	.	1	1	1	.	1	.	.	1	.	1	.	1
4	1	.	1	1	.	1	.	1	.	1	1	.	.	.
3	.	1	1	2	.	1	.	2	2	.	2	2	.	2
2	.	1	3	2	2	5	4	8	2	3
1	1	1	4	5	5	5	8	5	6	4	2	1

FIGURE 27. The number of synapses received by a neuron in the motor cortex plotted against its mean diameter. Each number on the graph indicates the number of neurons having that combination of mean diameter and number of synapses. Note the neurons receiving the largest numbers of synapses do not in general have a particularly large mean diameter and that most of the largest diameter cells do not receive many more synapses than the small neurons.

mean cell diameter																				
μm ...		6	7	8	9	10	11	12	13	14	15	16	17	18	19	20				
number of synapses																				
16				
15				
14				
13				
12				
11				
10	1				
9				
8				
7				
6	.	.	.	1	.	1				
5	1				
4	1	1	1	.	.	.				
3	.	.	1	1	2	2	7	3	1	1	1	.				
2	.	.	3	4	4	4	6	5	2	.	3	1				
1	.	2	1	6	15	8	6	4	4	4	2				

FIGURE 28. The number of synapses received by a neuron in the somatic sensory cortex plotted against its mean diameter. The numbers on the graph represent the numbers of neurons having that combination of mean diameter and number of synapses.

having that combination of size and number of synapses. It can be seen in both areas that a small proportion of the cells receives a large number of synapses but in general there is only a small increase in the number of synapses per cell with size; this indicates that the large numbers of synapses which are found on a proportion of cells is a reflection of a genuinely high synaptic density and not just a consequence of the large size of some cells.

A group of cells is usually recognized as a distinct class if the cells in it tend to have a *certain set of features* occurring together. A correlation matrix was performed by computer on all the cells of the motor cortex sample (figure 29) to see which features, if any, of these cells tended to occur together and to see if any particular groupings of features emerged from the unclassified cells to give independent evidence as to what the groups of cells present were. In the

	depth from pia	mean diameter	area			cytoplasm/nucleus	apical dendrite	no. of dendrites	no. of synapses	asymmetrics	nuclear indentations	dark nucleus	endoplasmic reticulum	merging cytoplasm
			total	nucleus	cytoplasm									
depth from pia	○	○	○	○	○	○	○	○	○	○	+	-	+	-
mean diameter	○	○	+	+	+	+	+	+	+	+	○	-	+	○
total	○	+	○	+	+	+	+	+	○	○	○	-	+	○
nucleus	○	+	+	○	+	○	+	+	+	○	○	-	+	○
cytoplasm	○	+	+	+	+	+	+	+	+	○	○	-	+	○
cytoplasm/nucleus	○	+	+	○	+	○	○	+	+	○	○	-	+	○
apical dendrite	○	+	+	+	+	○	+	-	+	○	○	-	○	○
no. of dendrites	○	+	+	+	+	○	+	○	○	○	○	-	○	○
no. of synapses	○	+	+	○	+	+	-	○	+	○	○	-	○	○
asymmetric synapses	○	○	○	-	+	+	-	+	○	○	○	-	○	○
nuclear indentations	+	○	○	○	○	○	○	○	○	○	+	-	○	○
dark nucleus	-	-	-	-	-	○	○	○	○	+	○	-	○	○
endoplasmic reticulum	+	+	+	+	+	+	○	+	+	○	-	○	○	○
merging cytoplasm	-	○	○	○	○	○	○	○	○	○	○	○	○	○

FIGURE 29. A correlation matrix of the parameters determined for each cell in the motor cortex. +, Statistically significant positive correlation between the two features in this population of neurons; -, significant negative correlation; ○, no statistically significant correlation.

matrix, '+' indicates that the features shown in the two intersecting columns were found together in the sample more frequently than would be predicted by chance, this being statistically significant at at least the 5% level. Similarly, '-' indicates that the two features were found together less frequently than chance would predict at the same probability level, that is that the features tended to be mutually exclusive.

The presence of an apical dendrite can be seen from the matrix to correlate with increasing mean cell diameter and increasing total, nuclear and cytoplasmic area, but not with a high ratio of cytoplasmic to nuclear area; an apical dendrite is therefore found more commonly on the larger cells of the sample. An apical dendrite also correlates with cells having more dendrites (although in itself it must mean that the cell has at least one) and the presence of an apical dendrite is inversely correlated with the number of synapses received by the cell and with the presence of asymmetric synapses. This grouping of features is in fact that of pyramidal cells and so this confirms the presently accepted classification.

The matrix shows that overall the number of synapses received by a cell increases with

mean cell diameter and total area. In contrast to apical dendrites, however, the number of synapses correlates with increase in the area of cytoplasm and in the ratio of cytoplasmic to nuclear area, but not with the area of the nucleus, so that it is cells with abundant cytoplasm rather than just large cells which tend to receive large numbers of synapses. The presence of large numbers of synapses can also be seen to be associated with asymmetric synapses and clumps of endoplasmic reticulum. This grouping of features corresponds to that described on the basis of qualitative evidence to the features of large stellate cells.

Neither the presence of an apical dendrite nor the number of synapses received by the cell correlates with the presence of a dark nucleus, so this does not appear to be a significant feature of either of the first two groupings. The presence of a dark nucleus can however be seen to correlate with a number of other features. It is inversely correlated with the depth of the cell from the pial surface and so occurs more frequently in cells from the more superficial layers of the cortex. It is also inversely correlated with mean cell diameter and total nuclear and cytoplasmic area and so occurs mainly in small cells. A dark nucleus also correlates inversely with the number of dendrites and the presence of clumps of endoplasmic reticulum and so cells with dark nuclei are not often seen with dendrites arising from the soma and have sparse endoplasmic reticulum. A dark nucleus also tends to be indented. This cluster of features, shown to occur together in the cells of this unselected sample, corresponds to the features attributed to small stellate cells on qualitative evidence; none of these features shows a similar correlation with an apical dendrite or the number of synapses present. These results therefore confirm independently that these small stellate cells form a separate distinct population in the cortex.

It is of interest that nuclear indentations, as well as being found more frequently in dark nuclei which occur towards the pial surface, also increase overall with depth from the pia. This apparent contradiction occurs because, although a greater proportion of dark nuclei are indented, in fact most indentations occur in nuclei of pyramidal cells which form the greatest proportion of the population and for some reason the pyramidal indentations increase with depth (see below). The matrix also confirms quantitatively that an increase in cell diameter goes with an increase in the ratio of cytoplasmic to nuclear area and also a greater frequency of clumps of endoplasmic reticulum. This confirms observations made qualitatively on pyramids above. There was a very close correlation between the mean diameter of a cell and its total area as measured here and they were effectively interchangeable. Therefore, because mean diameter is the simpler measurement to make, this was the only measure of cell size used in the somatic sensory cortex.

The correlation matrix thus shows three significant clusters of features which occur together in the cells of this unselected sample and these three sets of features correspond to the descriptions of pyramidal, large stellate and small stellate cell types which were made using qualitative evidence.

(ii) *Results classified by cell type*

The proportions of the different cell types and their laminar distribution. After the data in the previous section had been obtained, the cells from both areas were classified into pyramidal, large stellate and small stellate types using the criteria described above under the qualitative results. The proportions of each type of cell in the two cortical areas are remarkably similar (table 1); pyramidal cells account for more than two-thirds of the cells in each area and small stellate

TABLE 1. THE PROPORTIONS OF THE DIFFERENT CELL TYPES IN THE MOTOR AND SOMATIC SENSORY CORTICES

(Figures in parentheses are percentages.)

	motor cortex	somatic sensory cortex (area 3b)
total number of cells	107	110
pyramidal cells	77 (72)	79 (72)
large stellate cells	8 (7)	5 (5)
small stellate cells	22 (21)	26 (23)

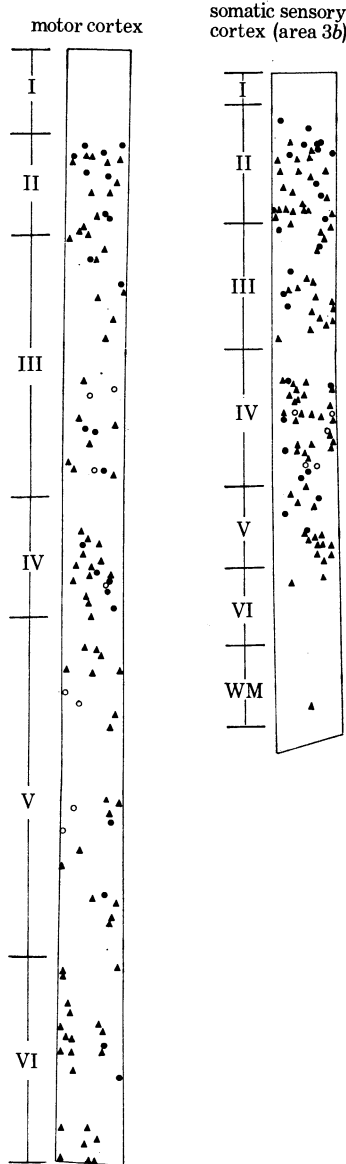


FIGURE 30

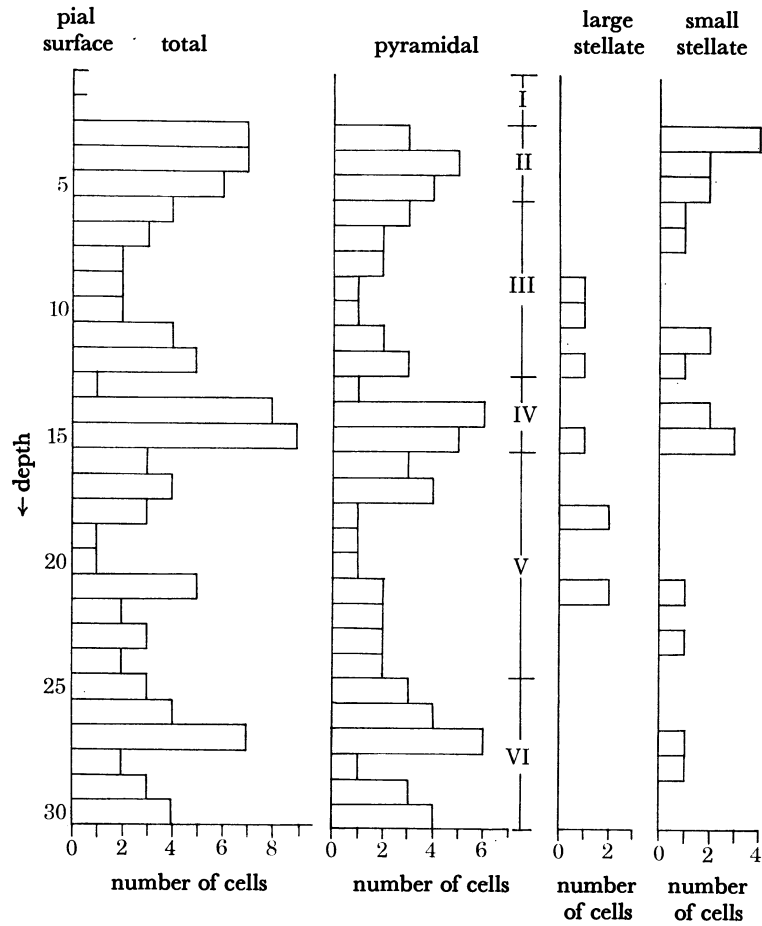


FIGURE 31

FIGURE 30. Maps of the strips of motor cortex and somatic sensory cortex studied quantitatively showing the position and type of each cell. The neuron shown in the white matter of area 3b was surrounded by myelinated fibres. It has been included with layer VI for analysis. ▲, Pyramidal cell; ●, small stellate cell; ○, large stellate cell.

FIGURE 31. Histograms showing the distribution of total numbers of cells and of each cell type against depth from the surface in the motor cortex.

cells form the majority of the remainder. The distributions of the cells through the depth of the cortex in the two areas are shown in the maps of figure 30 and the histograms of figures 31 and 32. The smaller thickness of the somatic sensory cortex is compensated for by the denser packing of its cells, so that the total numbers of cells in the two equal width strips are remarkably similar. From the map and histograms of the motor cortex (figures 30 and 31) it

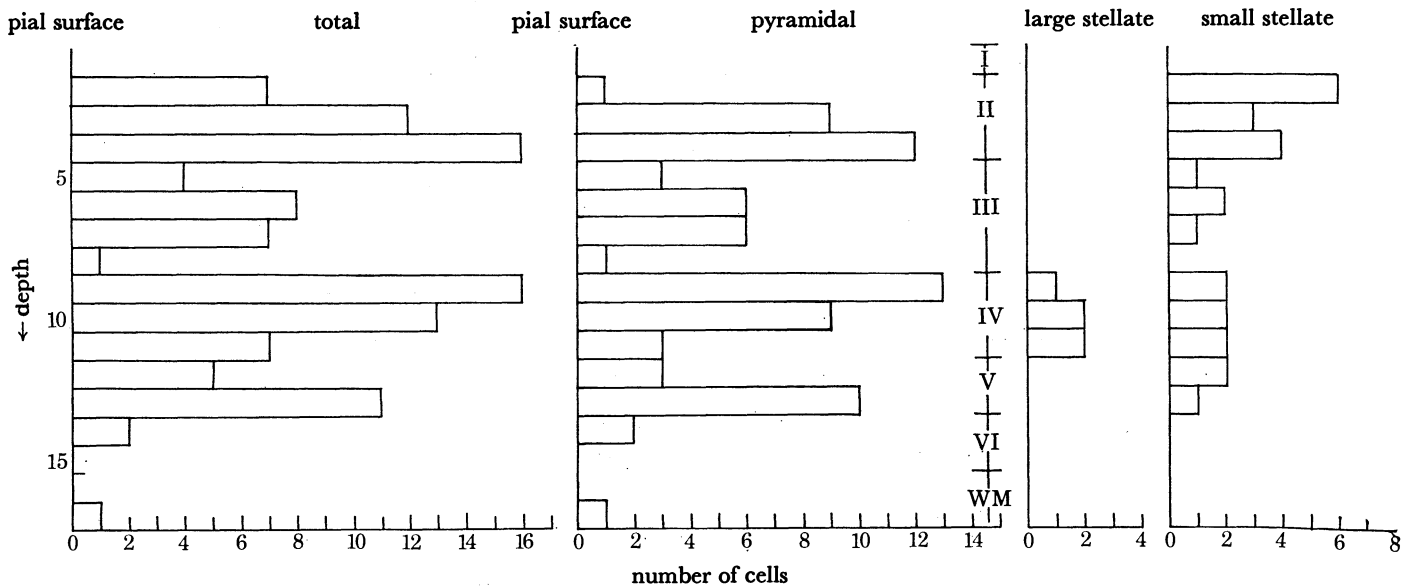


FIGURE 32. Histogram showing the distribution of total numbers of cells and of each cell type against depth from the surface in the somatic sensory cortex.

TABLE 2. THE NUMBERS AND PROPORTIONS OF THE DIFFERENT CELL TYPES IN DIFFERENT LAYERS OF THE MOTOR AND SOMATIC SENSORY CORTICES

(Figures in parentheses are percentages within that lamina.)

layer ...	cell type			total
	pyramid	large stellate	small stellate	
motor cortex				
I	0	0	0	0
II	12 (60)	0 (—)	8 (40)	20
III	14 (64)	3 (14)	5 (22)	22
IV	12 (66)	1 (—)	5 (28)	18
V	18 (75)	4 (17)	2 (8)	24
VI	21 (91)	0 (—)	2 (9)	23
total	77	8	22	107
somatic sensory cortex				
I	0	0	0	0
II	22 (63)	0	13 (37)	35
III	16 (80)	0	4 (20)	20
IV	25 (69)	5 (14)	6 (17)	36
V	13 (81)	0	3 (19)	16
VI	2	0	0	2
WM	1	0	0	1
total	79	5	26	110

can be seen that there are relative concentrations of cells in layer II and layer IV and that there are definite sparse regions at the boundary of layers III and IV and in the middle of layer V. Although care must be taken in interpreting the results from a narrow strip of cortex, it seems likely that these gaps are genuine and that they correspond to the outer and inner bands of Baillarger. The somatic sensory cortex shows similar concentrations of cells in layers II and IV and similar gaps at the junction of layers III and IV and in the upper part of layer V (figure 32). In figures 31 and 32 it can be seen in both areas that pyramidal cells occur in all layers except layer I and are more densely packed in layers II, IV and VI. In the motor cortex the large stellate cells occur in a band extending from the middle of layer III through layer IV to the middle of layer V whereas in area 3*b* of the somatic sensory cortex they are restricted to layer IV. The small stellate cells are most frequent in layer II in both areas but also occur in all the other cortical layers of the maps except layer I. The proportions of each

TABLE 3. NUMBERS AND PROPORTIONS OF THE DIFFERENT CELL TYPES IN A MAP OF THE MOTOR CORTEX PARALLEL TO THE PIA IN LAYER IV

(Figures in parentheses are percentages.)

pyramidal	17 (52)	
large stellate	5 (15)	} (48)
small stellate	11 (33)	

33

cell type in the different layers of the cortex are shown in table 2. Although the numbers in some groups are small, it is clear that up to half the cells in layer II of both cortical areas are small stellate cells and that this proportion falls off at greater depths from the pial surface. The proportion of pyramids increases progressively in the deeper layers of the motor cortex while in the somatic sensory cortex there is a relatively greater localization of stellate cells to layer IV with a correspondingly smaller proportion of stellate cells in layer III. A study was also made of a section taken parallel to the pial surface from layer IV of the motor cortex to obtain a larger sample of cells (table 3); the proportion of large stellate cells is in agreement with that in the adjacent laminae III and V of the first motor cortex map and is close to the proportion of large stellate cells in layer IV of the somatic sensory cortex.

Cell sizes. In both cortical areas most of the pyramids form one distribution of cell size (figure 33) and there is only one cell which is markedly larger than the rest, but pyramids in the motor cortex have a greater mean diameter (15.2 μm) than those in the somatic sensory cortex (12.3 μm), with a ratio of diameters of 1.21:1. Cell somata are however three dimensional objects. If one assumes that they approximate to a sphere then their volume is proportional to the cube of their radius and on this basis the mean volume of motor cortex pyramids is 1.77 times that of those in area 3*b* of the somatic sensory cortex.

The size distributions of large and small stellate cells in the two cortical areas (figure 34) confirm the size ranges described qualitatively and in the motor cortex there is little overlap between the size distributions of the two stellate cell types. The mean diameter of large stellate cells in the motor cortex was 16.6 μm and of small stellate cells 10.4 μm and so size is a useful distinguishing feature in this area. In the somatic sensory cortex the small stellate cells were slightly smaller than in the motor cortex (mean diameter 9.6 μm), but as the large stellate cells were considerably smaller (mean diameter 10.8 μm) there is considerable overlap

between the size ranges of the two stellate cell types in the sensory area. The two types are however still distinguished by the other features described above, in particular by the difference in the numbers of synapses that the cells of the two groups receive.

The diameters of cells differ with the depth of the cell from the pia. The smallest cells occurred in layer II and in layer IV in both areas, with a few immediately above the conven-

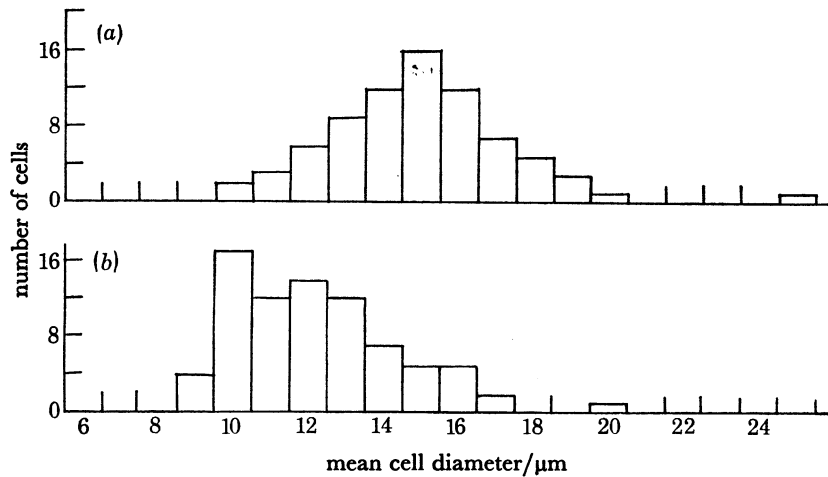


FIGURE 33. Histograms showing the distributions of the mean diameters of pyramidal cells in (a) the motor cortex and (b) somatic sensory cortex (area 3b).

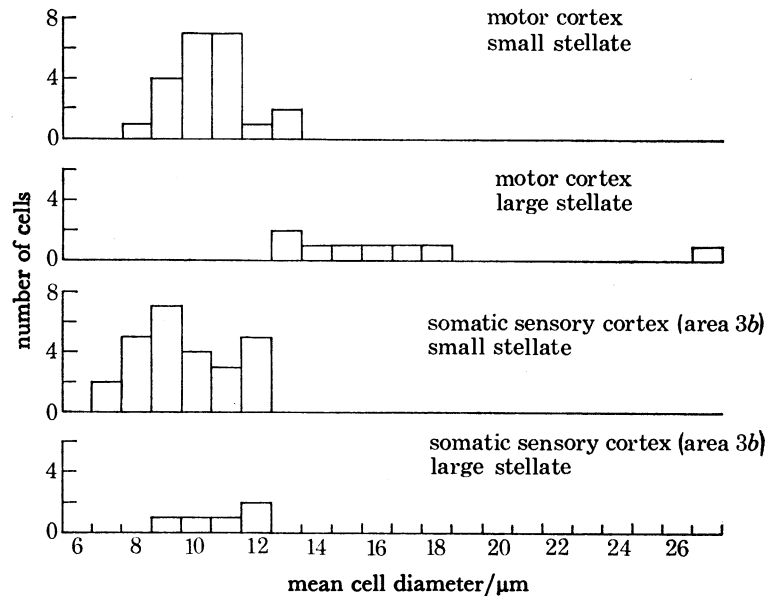


FIGURE 34. Histograms showing the size distributions of small and large stellate cells in the motor and somatic sensory cortices.

tional narrow layer IV in the motor cortex. The concentrations of cells at these levels seen in the maps and depth distribution histograms (figures 30-32) consist predominantly of small and medium sized cells, this being more marked in the somatic sensory cortex. These two bands of small and medium sized cells probably correspond to the granule cell bands and analysis of the cell types present showed that they were predominantly small stellate and small pyramidal

cells occurring in similar proportions. In layer IV of the somatic sensory cortex, large stellate cells were also present in the band but were generally slightly larger in size.

The largest cells in both areas occurred in layers III and V and the mean diameter of all cells and of pyramids was greatest in these two laminae in both cortical areas. The mean diameter of pyramidal cells in layer V did not differ significantly from that of those in layer III although in somatic sensory cortex the mean diameter of layer V pyramids was greater than that of those in layer III. It may be that the observed differences in cell sizes between these two layers in sections stained by the Nissl method is due to a small proportion of very large cells being present in layer V, especially in the motor cortex, rather than to the general population of cells in layer V being larger.

Numbers of synapses. Most pyramids in both areas receive only one or two axosomatic synapses in a single section (figure 35). There are more pyramids receiving four or five synapses in the motor cortex, on the larger cells, and the mean number of synapses received by a pyramid in a single section of motor cortex (1.79) is slightly greater than in the somatic sensory cortex (1.68). Being a small positive integer, it would be expected that the distribution of the numbers of synapses on pyramidal cells found by this sampling method should follow a Poisson distribution if the density of synapses on pyramidal cell somata is constant. Analysis of these distributions from both cortical areas shows that they in fact do so (χ^2 motor cortex 0.694, 3 d.f.; somatic sensory cortex 0.297, 2 d.f.). The observed and predicted distributions for each area are compared in figure 35. The Poisson distribution is however truncated because those neurons which happened not to receive a synapse in the section studied were not included in the sample. This number can be estimated by mathematically completing the Poisson distribution and in the motor cortex was 21 cells and in the somatic sensory cortex was 25 cells. This means that about 21% of the pyramids in the motor cortex and 24% in the somatic sensory cortex received no synapse in the section studied and were therefore excluded from the sample. The estimates of the numbers of pyramids in the two areas are therefore correspondingly low but the difference is very similar for the two areas.

If the stellate cell somata formed a single population with a single synaptic density like the pyramidal cells, the distribution of the numbers of synapses per cell profile should likewise follow a Poisson distribution. In figure 36, the distributions for all the stellate cells are compared to Poisson distributions having the same mean. In the motor cortex the observed distribution differs from the predicted distribution in having an excess of cells with either very few synapses or a large number of synapses and a relative deficit of cells around the mean value of four of the predicted Poisson distribution. This deviation from the predicted Poisson distribution is statistically significant ($\chi^2 = 12.91$, 3 d.f.; $P < 0.02$). In the somatic sensory cortex there are similar, but less marked, differences between the observed and predicted populations and these do not reach statistical significance although the fit between the two curves is poor ($\chi^2 = 2.77$, 3 d.f.), particularly when compared to those for the pyramidal cells in both areas. This strongly suggests that the stellate cells do not form a single homogeneous population. Figure 37 shows the distributions in the motor cortex and figure 38 those in the somatic sensory cortex after splitting into large and small stellate cell types; the distributions of both cell types in both areas can now be fitted by Poisson curves. The fit for small stellate cells in both areas is satisfactory (χ^2 motor cortex 0.39, 2 d.f.; somatic sensory cortex 0.62, 2 d.f.) while in the case of large stellate cells the number of cells present is too small to test statistically although the fit appears reasonable visually. The mean number of synapses on a small stellate

cell in the motor cortex is 2.2 while on a large stellate profile it is 8.9 and in the somatic sensory cortex the mean for a small stellate profile is 1.8 and for a large stellate profile is 6.2; this is one of the most important distinctions between the two stellate cell types. As in the case of the pyramidal cells, the numbers of each cell type in both areas which receive no synapses can be estimated by completing the Poisson distribution. For small stellate cells it is 4 in the motor cortex and 7 in the somatic sensory cortex, while it is very unlikely that any large stellate cells

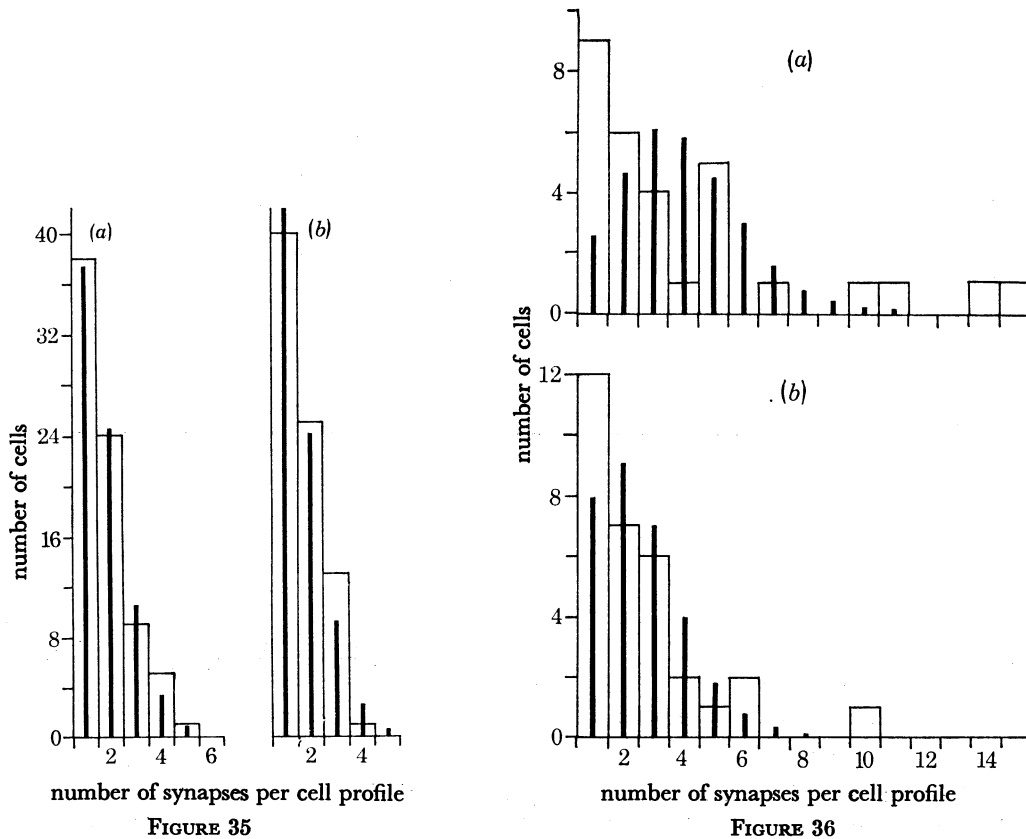


FIGURE 35. Histograms showing the distributions of the numbers of synapses received by pyramidal cell profiles in the section studied in (a) motor and (b) somatic sensory cortices. The black bars show Poisson distributions with the same mean. Note the close correspondence between the observed and predicted distributions for both motor and somatic sensory cortices.

FIGURE 36. Histograms showing the distributions of the numbers of synapses received by stellate cell somata in (a) motor and (b) somatic sensory cortices, all stellate cells being considered as a single population. The black bars show Poisson distributions with the same mean. Note the marked excess of cells observed with very large and small numbers of synapses compared to the predicted distribution in the motor cortex with a relative deficiency around the mean value. Similar discrepancies are apparent in the somatic sensory cortex but are less marked.

in either area will fail to receive a synapse in any particular section. This means that overall, the proportion of large stellate cells will have been overestimated in both areas in relation to both the other cell types because of the criteria which have to be adopted; but since this will be similar in both areas a fair comparison of the proportions of the different cell types can be made; recalculation using these figures reduced the proportion of large stellate cells by 1% in both cortical areas.

The relation between the numbers of synapses received by a cell and mean cell diameter is

shown for the three cell types in the two cortical areas in figures 39–41. The number at each point indicates the number of cells of that type having that combination of number of synapses and cell diameter. By comparison with the overall graphs of these two parameters (figures 27 & 28) it can be seen that the three different cell types occur predominantly in different regions of the graph. Most small stellate cells occur in the region corresponding to a small

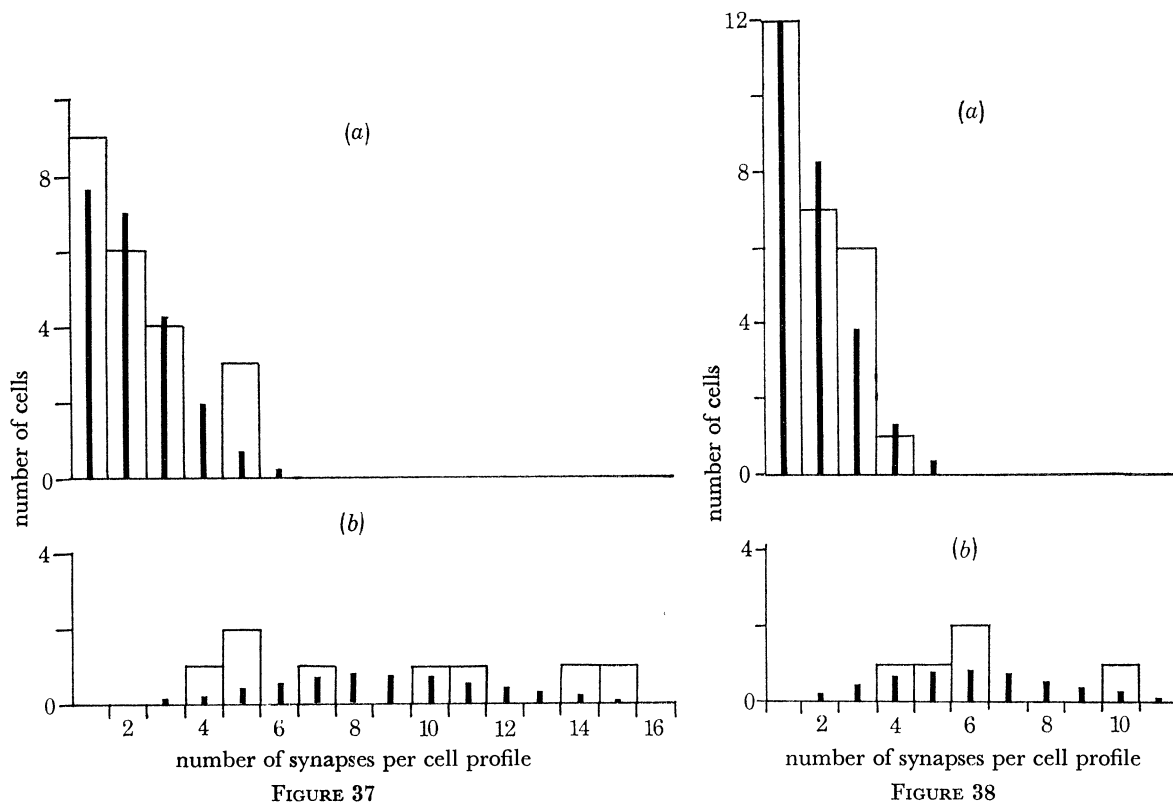


FIGURE 37. The histograms of the number of synapses per cell profile for (a) small and (b) large stellate cells in the motor cortex are compared to predicted Poisson distributions (black bars). That for small stellate cells is a reasonable fit statistically; the number of large stellate cells observed is too small for statistical comparison or to give an accurate estimate of the population distribution although the fit appears reasonable visually.

FIGURE 38. The histograms of the numbers of synapses per cell profile for (a) small and (b) large stellate cells in the somatic sensory cortex are compared to predicted Poisson distributions (black bars). The comparison for small stellate cells is a reasonable fit statistically and the comparison for large stellate cells is a reasonable visual fit although too few large stellate cells were observed for statistical comparison.

mean diameter and a small number of synapses in both areas; the pyramidal population overlaps with this at the lower end of its size range but is mostly larger and there is only a slight tendency for the number of synapses to increase with the size of the pyramidal cells. In contrast to these two groups the large stellate population extends across a region of moderate to large numbers of synapses, but the size range of the cells is very similar to that of the pyramids. Use of these two parameters will therefore separate to a large extent the three cell types in both cortical areas. In particular, when the two stellate cell populations are plotted on the same graph, they may be separated by a straight line as shown in the samples from both the motor and somatic sensory cortices. Thus the cells of the two stellate populations which overlap with regard either to mean diameter (figure 34) or number of synapses (figures 37 and 38)

do not overlap with regard to the other of these parameters and no cells in the two groups in fact overlap with respect to both diameter and number of synapses received.

Number of dendrites per cell. In the sections cut accurately perpendicular to the pial surface, the majority of pyramidal and large stellate cells give rise to at least one dendrite in a section, but the majority of small stellate cells do not (figure 42). Even when pyramids with apical




FIGURE 39. Graphs showing the combined distributions of mean cell diameter and the number of synapses received for pyramidal cells in (a) motor and (b) somatic sensory cortices. Each number on the graph indicates the number of pyramids having that combination of mean diameter and number of synapses (cf. the distributions for all cells in figures 27 & 28).

dendrites are excluded the remaining pyramids are still more likely to give rise to a dendrite than is a small stellate cell.

Nuclear indentations and endoplasmic reticulum. Nuclear indentations were most frequent in small stellate cells, but were also often present in large stellate cells. They were also present in about half the pyramidal cells in layers V and VI but were rare in the pyramidal cells of layers II and III. They were therefore a useful distinguishing feature between pyramids and small stellate cells in the supragranular layers.

Most large stellate cells contained stacks of endoplasmic reticulum, but these were rare in small stellate cells. More pyramids contained stacks of endoplasmic reticulum in the motor cortex and these were more frequent in pyramids in the infragranular layers.

Asymmetric synapses. The frequencies with which clearly identifiable asymmetric synapses were found on the different cell types in the two cortical areas are shown in table 4. No pyramids were found to receive any asymmetric synapses but they were present on almost all the large stellate cells in both areas. They were found on a proportion of small stellate cells but the small number of synapses on each cell reduced the chance of finding a clearly identifiable asymmetric one.

Dark nuclei. The nuclei of 13 small stellate cells in each cortical area were judged to be dark (table 4) in that their chromatin appeared dense and occurred in clumps (figure 14). This total was about half the small stellate cell population in each area. No systematic differences

were found in the incidence of dark nuclei in the different cortical laminae. No pyramidal nuclei were dark but one large stellate nucleus in the motor cortex and three in the somatic sensory cortex were judged to be dark.

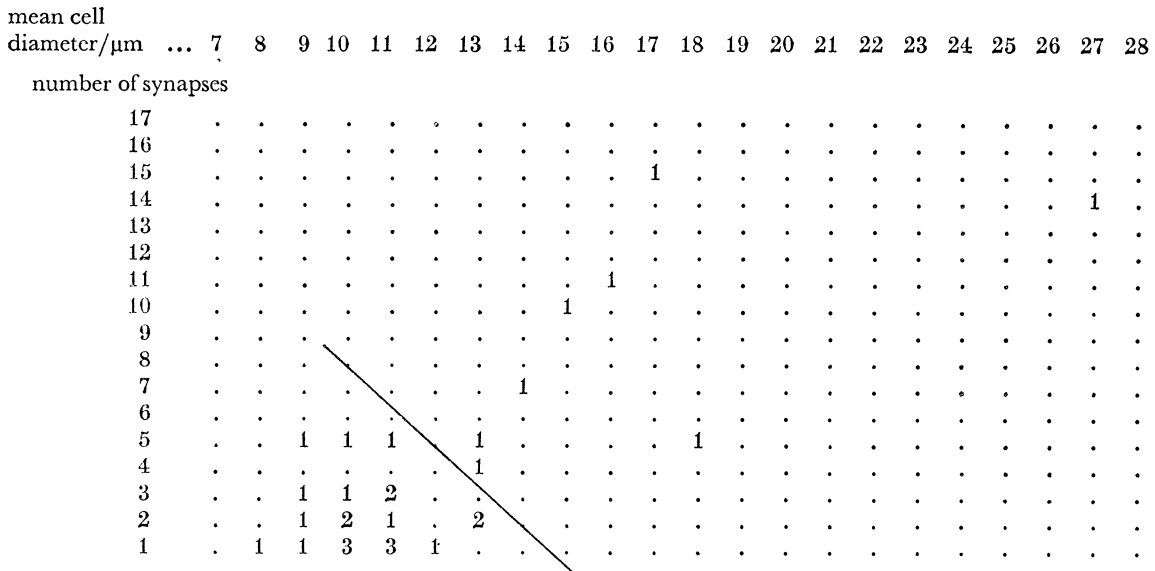


FIGURE 40. Graph showing the combined distributions of mean cell diameter and number of synapses received for all stellate cells in the motor cortex. A straight line drawn on the graph separates the large and small stellate populations to the right and left of the line respectively. There is a much steeper rise in the number of synapses received with increasing cell diameter for large stellate cells in comparison to pyramidal cells (figures 27 & 39).

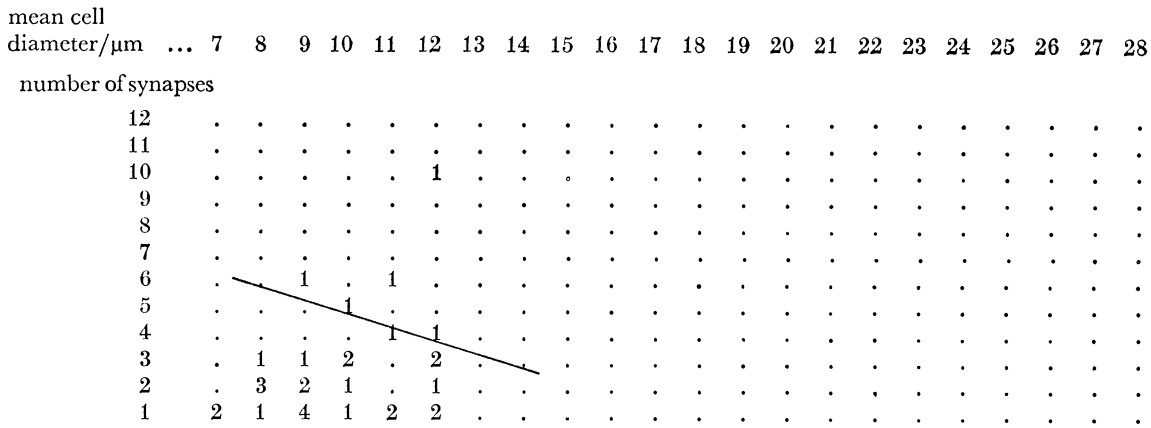


FIGURE 41. Graph showing the combined distributions of mean cell diameter and number of synapses received for all stellate cells in the somatic sensory cortex. The straight line drawn on the graph as shown separates the large and small stellate populations to the right and left of the line respectively.

DISCUSSION

Descriptions of non-pyramidal cells from previous e.m. studies have concentrated upon those cells which are most strikingly different from pyramidal cells and in particular those receiving numerous axo-somatic synapses and clearly identifiable asymmetric synapses. The present study has confirmed these previous observations made mainly in sensory and parietal cortical areas and has extended them to the motor cortex and the primate. However, a con-

siderable proportion of the cells found clearly did not correspond to previous descriptions of stellate cells, but also had features which made it clear that they were not pyramidal cells; these cells have been termed small stellate cells. They may be distinguished from pyramidal cells because they can be shown in serial sections to lack an apical dendrite, they receive asymmetric synapses, the dendrites to which they give rise are usually beaded and they may have an axon initial segment directed towards the cortical surface. The presence of a population

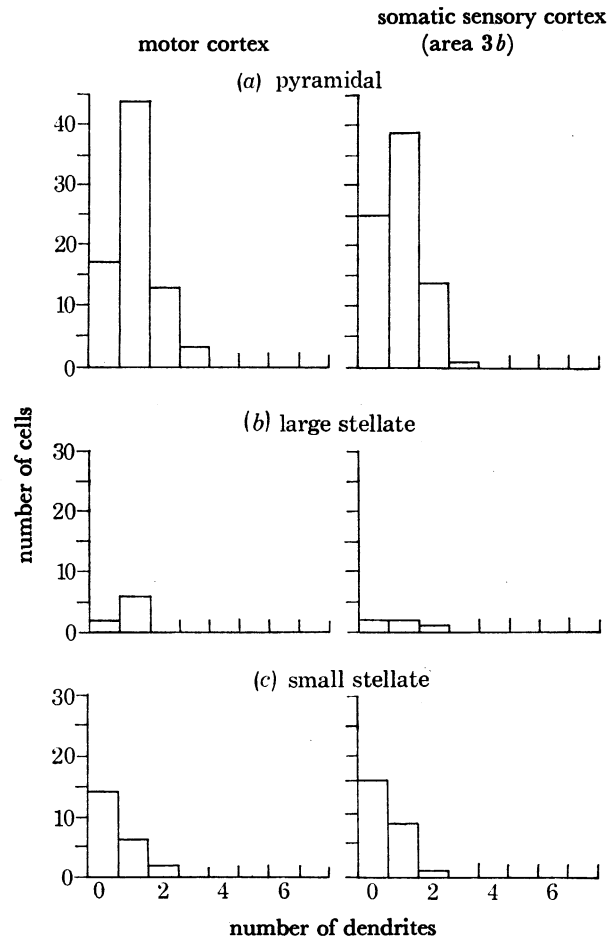


FIGURE 42. Histograms showing the numbers of dendrites arising from the cell soma in the sections studied for (a) pyramidal cells, (b) large stellate cells and (c) small stellate cells in both motor and somatic sensory cortices.

TABLE 4. FREQUENCIES OF ASYMMETRIC SYNAPSES AND DARK NUCLEI FOR NEURONS OF EACH TYPE

	total	asymmetric synapses	dark nuclei
motor cortex			
pyramidal	77	0	0
large stellate	8	8	1
small stellate	22	3	13
somatic sensory cortex (area 3b)			
pyramidal	79	0	0
large stellate	5	4	3
small stellate	26	6	13

of small cells lacking apical dendrites is also shown by the graphs of the frequency of occurrence of an apical dendrite against size in the overall cell population (figures 24 and 25). A number of other features have also been found to distinguish the population of small stellate cells from that of pyramidal cells, including their small size, their incidence of dark nuclei, the low frequency of dendrites found arising from their somata in a single section, their rounded shape and, in the superficial laminae, their high incidence of nuclear indentations.

This group of small stellate cells clearly differs from previous descriptions of typical stellate cells (Colonnier 1968; Szentágothai 1969; Jones & Powell 1970*a*; Lund & Lund 1970; Peters 1971; Garey 1971) as they do not receive the large number of synapses described as contacting typical stellate cell somata and they lack the abundant cytoplasm, endoplasmic reticulum and the high density of cytoplasmic organelles described as typical of these cells. Also the majority of small stellate cells occur in layer II of the cortex whereas previous descriptions have concentrated largely on those stellate cells which occur in layer IV of sensory cortical areas. The motor cortex also contains stellate cells corresponding closely to previous descriptions and these have been termed here large stellate cells. In the motor cortex, where the distinction was first made, there is a clear size difference between the two stellate cell types but it should be emphasized that this is by no means the most important difference and in the somatic sensory cortex these other features become much more important in differentiating the two types of cell because the size difference is much less marked.

Having established that the sensori-motor cortex contains a proportion of non-pyramidal cells which do not correspond to previous descriptions of stellate or non-pyramidal cells, it is necessary to determine whether these cells represent an extension of the stellate cell population described previously or whether they form a separate population. The impression gained from studying the cortex qualitatively is that the stellate cells form two distinct groups with different sets of features rather than forming a continuum, but there is a risk of selecting 'typical' cells of each type for study in this way and so gaining an artificial impression of a split. This danger is avoided by studying a random sample of cells and, although there was inevitably a little overlap, most stellate cells in the sample were clearly of one or other type, particularly in the motor cortex. The correlation matrix showed this objectively in that a cell with a large number of synapses, a feature of large stellate cells, also tended to have the other features described for this type and a cell with a dark nucleus, a feature mostly of small stellate cells, tended to have the other features of small stellate cells. Conversely, there was no significant association of features of one stellate type with the features of the other type. If the stellate cells formed a single population, the matrix should show neither of the effects since the chance of finding a particular feature should then be the same in any stellate cell and all the features of the cell type should correlate together.

A second approach to the problem of whether the stellate cells form one or more than one population is to examine parameters of a random sample of the stellate population, such as that taken, to see whether those parameters are distributed as would be expected for a single population. The random samples of the pyramidal populations serve as useful controls for this. In a single population of cells it would be expected that the density of axo-somatic synapses on different cells would be very similar. A single section through the centre of one of these neurons should sample these axo-somatic synapses randomly and because the numbers of synapses found in a single section is a small positive integer, the numbers of synapses seen per cell profile (figures 35–38) should approximate to Poisson distributions. This is so for pyramidal

cells in both areas (figure 35) but when all the stellate cells are taken together, the distribution differs significantly from a Poisson distribution in the motor cortex (figure 36); the deviation is due to the combination of the proportion of the cells having large numbers of synapses with the majority of cells which have only a small number of synapses. These findings therefore indicate that, unlike the pyramidal cells, the stellate cells do not form a single population. When split into large and small types, however, the distributions for both large and small stellate cells in both areas do not differ significantly from Poisson distributions (figures 37 & 38). This therefore confirms that there is more than one population of stellate cells in each area.

When the number of synapses per cell is plotted against mean cell diameter for all stellate cells (figures 40 and 41) it can similarly be seen in both areas that there is a cluster of cells in the region of small size and low number of synapses and then a number of cells spread across the region of moderate to large size and large number of synapses. This contrasts with the more uniform distribution of the pyramidal population and it seems unlikely that this sort of cluster and spread would be produced by a single population of cells. It would however be explained by there being two distinct stellate cell populations.

It is evident therefore in normal material that two types of stellate cell may be recognized on the basis of clusters of features which tend to go together and examination of the distributions of various parameters in a randomly selected population of stellate cells also indicates that this population consists of more than one component. Following thalamic lesions only large-type stellate cells are found to receive degenerating axo-somatic synapses (Sloper 1973*b*; Sloper & Powell 1979*b*) and the range of mean diameters and the distribution of numbers of synapses per cell for these cells correspond to those of the large stellate cell population described here. This difference in connections thus confirms the existence of two populations of stellate cells. The main features of each cell type are summarized in table 5.

Comparison of different cortical areas

It has generally been thought on the basis of light microscopy, using mainly the Nissl technique, that the motor cortex consisted predominantly of pyramidal cells whereas most of the cells in the somatic sensory cortex were stellate cells. The finding in this study that the motor cortex and area 3*b* of the somatic sensory cortex contain very similar proportions of pyramidal and stellate cells as judged by electron microscopic criteria was therefore unexpected. It can be seen from the data taken before classification however that both cortical areas contain only a small proportion of cells with the large number of synapses typical of previous descriptions of stellate cells, or of large stellate cells as described here, and both areas contain similar proportions of cells with dark nuclei, a feature predominantly of small stellate cells. Following classification, the parameters of each of the three cell types in the two areas are also very similar and it is therefore very unlikely that the proportion of stellate cells in the sample from the somatic sensory cortex could have been seriously underestimated. Because these samples of cells represent only one strip from each cortical area there must be some caution about regarding them as typical of each area. However, the results from them are in general accord with the impression gained from comparing the two cortical areas qualitatively and it seems likely therefore that these samples are representative. The same three cell types have now been recognized in area 17 of the visual cortex (Tömböl 1974) and a quantitative survey was performed taking only those cells having nucleoli in the section studied. Although the other criteria used were the same, this difference is likely to give a slight bias towards smaller cells

TABLE 5. SUMMARY OF THE FEATURES OF THE DIFFERENT TYPES OF CELL SOMATA

cell type	apical dendrites yes	nucleus	cytoplasm	synapses	size	shape	connections	layers
pyramidal		light; often indented in layers IV, V and VI	amount varies with cell size; larger cells contain stacks of endoplasmic reticulum	only symmetrical	motor 10-50 μ m somatic 9-20 + μ m	pyramidal	—	II-VI
large stellate	no	moderately dark; some dark in somatic sensory cortex; may be indented	abundant; high concentration of mitochondria; frequent stacks of endoplasmic reticulum, especially in the motor cortex	many, both asymmetrical and symmetrical	motor 13-30 μ m somatic 9-12 μ m	rounded	receive thalamocortical and other afferents. gap junctions	motor lower III, IV and upper V somatic IV
small stellate	no	often dark; often indented	sparse; pale background and few organelles especially in round type	few; both asymmetrical and symmetrical	motor 9-12 μ m somatic 7-12 μ m	round or fusiform	—	II and some in all other laminae

and so the data in this study were analysed with respect only to those cells having nucleoli to make the results comparable. Thirty-six percent of the cells in the motor cortex and 41 % of those in the somatic sensory cortex had nucleoli in the section which confirms the slight bias towards smaller cells. The proportions of the three cell types using this additional criterion are compared with the results for the visual cortex in table 6 where it can be seen that they are very similar in all three areas of cortex. Since these different cortical areas represent what are thought to be extreme architectonic types, it seems a strong possibility that the proportions of the cell types may be very similar in intermediate cortical areas such as the parietal lobe and it is possible that this is so throughout the cerebral cortex.

TABLE 6. PERCENTAGES OF THE DIFFERENT CELL TYPES IN MOTOR, SOMATIC SENSORY AND VISUAL CORTICES FOR CELLS WITH NUCLEOLI ONLY

	motor cortex	somatic sensory (area 3 <i>b</i>)	visual cortex† (area 17)
pyramidal	64.0	60.0	59.0
large stellate	10.0	9.0	7.4
small stellate	26.0	31.0	33.6

† From Tömböl (1974).

The motor and somatic sensory cortices do however appear different when stained by the Nissl technique and there are undoubtedly many more cell somata in the motor cortex which appear pyramidal in shape. It seems likely that this is due to two factors. First, there is a greater proportion of larger pyramids in the motor cortex; the diameter of the apical dendrite is larger in proportion to that of the cell soma in larger cells, so that larger pyramids have a more obviously pyramidal shaped soma and this would be apparent in material stained by the Nissl method. The second factor is that the Nissl technique stains clumps of endoplasmic reticulum as Nissl substance and it is often these which outline the shape of the cell soma and apical dendrite. It has been found here that endoplasmic reticulum is more frequent in larger pyramids and since it often extends into the beginning of the apical dendrite it will make it more conspicuous. It therefore seems that the differences between the motor and somatic sensory cortices when stained by the Nissl technique are due to differences in the sizes of cells rather than to differences in cell type.

The similarity of the cell populations in the motor and somatic sensory areas is of considerable significance to both the understanding of the development of the neocortex and of its functioning. Since these two different areas of the adult neocortex contain the same numbers of cells through the depth, now extended to other neocortical areas (Rockel, Hiorns & Powell 1974) and the same proportions of the different cell types, the neocortex would appear to be more uniform than generally thought. There may be a basic principle that a cylinder of constant cross section taken through the full depth of the cortex of any area will contain the same number of cells with the same proportions of each type and it may be that this is a reflection of a constant functional subunit within the cortex with the basic mechanism of neuronal processing being similar throughout the neocortex.

The close similarity in the populations of neurons in the motor cortex and area 3*b* of the somatic sensory cortex means that the differences which are apparent between these two areas must be due to other factors. The average volume of cell somata in the motor cortex is almost

twice that of those in area 3*b* and it would be expected that the volumes of the dendritic ramifications of these cells will similarly be larger. This will to some extent account for the greater volume of neuropil in the motor cortex and so the greater spacing of cells and the greater thickness of this cortical area. There must presumably be a correspondingly greater number of axon terminals in the motor cortex since they do not obviously form a smaller proportion of the neuropil and it has been shown that there are many more synapses per cell in the motor cortex of the monkey compared to its visual cortex (Cragg 1967). Although there may be more extrinsic afferents to the motor cortex, there does not seem to be any striking difference in the connections studied (Sloper 1973*b*; Sloper & Powell 1979*b*) and all the extrinsic afferents together form only a small proportion of the terminals in the neocortex (Szentágothai 1964; Gruner, Hirsch & Sotelo 1974). There must be more extensive ramifications of the axons and axon collaterals of cells within the motor cortex and the main difference between the motor cortex and the somatic sensory cortex is probably that the cells of the motor cortex are more extensively interconnected with each other by these.

The other factor affecting the appearance of the cortex in sections stained by the Nissl method is the relative development of the different cortical laminae and the relationships of the fibre bands to these. As far as can be judged from this study, the fundamental laminar pattern is qualitatively the same in both cortical areas, but the deeper cortical layers are considerably thicker and contain a greater proportion of the cells in the motor cortex, as has been described previously (von Bonin & Bailey 1947). That this is a real difference is confirmed by the higher relative position of the band of thalamo-cortical degeneration in the motor cortex (Sloper 1973*b*; Jones 1975*a*; Sloper & Powell 1979*b*). Most cortical efferents arise from the deep layers and the differences in lamination of the two cortical areas may be due to the motor cortex giving rise to a larger efferent projection than area 3*b* of the somatic sensory cortex.

Correlation of electron microscope results with light microscopy

The classification of neurons in this study has been done entirely on the basis of features seen under the electron microscope and the two types of stellate cells have been described using ultrastructural criteria alone. In this section an attempt will be made to relate this classification to the different types of cells described by means of the Golgi technique by using morphological features which may be visualized by both methods. The equivalence of pyramidal cells seen with the Golgi method and electron microscopy is generally accepted although the ultrastructural features of spiny stellate cells described in the visual cortex appear to correspond more closely to those of a pyramid than a stellate cell (Le Vay 1973), particularly in that the cell somata receive only symmetrical synapses; possibly these cells should be regarded as modified pyramidal cells rather than as true stellate cells. The few spiny stellate cells present in the sensori-motor cortex of the monkey (Jones 1975*b*) will almost certainly have been classified as pyramids in the present study because of their ultrastructural features but it is unlikely that the small number present will have had any significant effect on the overall proportions of pyramidal and stellate cells.

Large stellate cells

With the electron microscope large stellate cells appear to form a relatively homogenous population. The cell soma is of medium to large size and usually round; the dendrites arise without an initial constriction, their outline is not markedly varicose and they tend to run in straight lines for some considerable distance. They also give rise to occasional spines, an uncommon feature for a non-pyramidal cell type and they make gap junctions with dendrites or somata, usually of the same cell type (Sloper 1972). In the motor cortex large stellate cells are found mainly in a horizontal band extending from the middle of layer III, through layer IV to the middle of layer V. The initial segment of these cells is similar in structure to that of a pyramid but may be orientated in any direction and is often curved. In the two examples where it has been possible to trace the initial segment far enough, it has been shown to give rise to a myelinated axon of similar diameter to itself at 23 and 24 μm from the cell soma, rather closer than with pyramidal cells.

Of the types of stellate cell described using the Golgi technique, the basket cell (Cajal 1911; Marin-Padilla 1969, 1970) which Jones (1975*b*) considered to correspond to his Type I has a number of features which match those of the large stellate cell. The cell soma is rounded and dendrites arise without an initial constriction; they have only a slightly varicose shape and tend to run in straight lines and bear occasional spines (Marin-Padilla 1969, 1970). Although comparisons of absolute size between different techniques and different species are unreliable, Type I cells are the largest type of non-pyramidal cell described by Jones (1975*b*); the largest non-pyramidal cells seen with the Golgi technique are of this type and the largest non-pyramidal cells seen with the electron microscope are of the large stellate type and with both methods these cells approach the size of Betz cells. Type I cells form between 15 and 25% of the non-pyramidal cells observed by Jones in area 3, whereas large stellate cells formed 16% of the sample of non-pyramidal cells from area 3*b* in the present study. Basket cells are found from the middle of layer III down to the middle of layer V in the motor cortex (Marin-Padilla 1969, 1970) and this laminar distribution corresponds to that of large stellate cells.

If the large stellate cell is the basket cell this implies that it gives rise to axon terminals which form synapses on to pyramidal cell somata and which are therefore of the symmetrical type. Since the dendrites and somata of large stellate cells are the site of termination of the proportion of thalamo-cortical terminals which does not contact spines (Sloper 1973*b*; Sloper & Powell 1979*b*) this may represent the disynaptic path by which thalamic afferents inhibit pyramidal tract cells (Branch & Martin 1958; Amassian & Weiner 1966).

Small stellate cells

Unlike the large stellate cells, the small stellate cells do not give the appearance of forming a homogeneous population and in particular there is electron microscopic evidence of differences between those with round and fusiform somata. Impregnation with the Golgi technique shows clear differences in the dendritic ramifications of round and fusiform small stellate cells and it would appear that most of the subdivisions of non-pyramidal cells recognized by light microscopy (e.g. Cajal 1911; Szentágothai 1973; Jones 1975*b*) fall within this electron microscopic group. Although it has not been possible to make detailed correlations, it seems likely that the round small stellate cells seen particularly in layer II correspond to the neurogliaform cells of Cajal (1911). The Golgi technique confirms the markedly varicose shape of the dendrites

of small stellate cells and the tendency for them to arise with an initial constriction. The pre-synaptic dendrites giving rise to the dendro-dendritic synapses seen in the motor cortex have the cytological features of dendrites of small stellate cells and are found in the deep layers of the cortex (Sloper 1971). Although it has not been possible to obtain any direct evidence as to their origin, it seems most likely that they arise from an infrequent type of fusiform small stellate cell; the laminar distribution and a detailed comparison of the shape of dendrites in Golgi and electron microscopic material suggests that this could be the 'cellule à double bouquet protoplasmique' (Cajal 1911; Colonnier 1966; Jones 1975*b*).

This work was supported by grants from the Medical and Science Research Councils.

REFERENCES

- Alksne, J. F., Blackstad, T. W., Walberg, F. & White, L. E. 1966 Electron microscopy of axon degeneration: a valuable tool in experimental neuroanatomy. *Rev. Anat. Emb. Cell Biol.* **39**, 6-32.
- Amassian, V. E. & Weiner, H. 1966 Monosynaptic and polysynaptic activation of pyramidal tract neurons by thalamic stimulation. In *The thalamus* (ed. D. P. Purpura & M. D. Yahr), pp. 255-282. New York: Columbia University Press.
- von Bonin, G. & Bailey, P. 1947 *The neocortex of Macaca mulatta*. Urbana, Illinois: The University of Illinois Press.
- Branch, C. L. & Martin, A. R. 1958 Inhibition of Betz cell activity by thalamic and cortical stimulation. *J. Neurophysiol.* **21**, 380-390.
- Cajal, S. R. y 1911 *Histologie du Système nerveux de l'Homme et des Vertébrés*, vol. 2. Paris: Maloine.
- Colonnier, M. 1966 The structural design of the neocortex. In *Brain and conscious experience* (ed. J. C. Eccles), pp. 1-23. Berlin: Springer-Verlag.
- Colonnier, M. 1968 Synaptic patterns on different cell types in the different laminae of the cat visual cortex. *Brain Res.* **9**, 268-287.
- Cragg, B. G. 1967 The density of synapses and neurones in the motor and visual areas of the cerebral cortex. *J. Anat.* **101**, 639-654.
- Cragg, B. G. 1976 Ultrastructural features of human cerebral cortex. *J. Anat.* **121**, 331-362.
- Garey, L. J. 1971 A light and electron microscopic study of the visual cortex of the cat and monkey. *Proc. R. Soc. Lond. B* **179**, 21-40.
- Gruner, J. E., Hirsch, J. C. & Sotelo, C. 1974 Ultrastructural features of the isolated suprasylvian gyrus in the cat. *J. comp. Neurol.* **154**, 1-28.
- Jones, E. G. 1975*a* Lamination and differential distribution of thalamic afferents within the sensory-motor cortex of the squirrel monkey. *J. comp. Neurol.* **160**, 167-204.
- Jones, E. G. 1975*b* Varieties and distribution of non-pyramidal cells in the somatic sensory cortex of the squirrel monkey. *J. comp. Neurol.* **160**, 205-268.
- Jones, E. G. & Powell, T. P. S. 1970*a* Electron microscopy of the somatic sensory cortex of the cat. I. Cell types and synaptic organization. *Phil. Trans. R. Soc. Lond. B* **257**, 1-11.
- Jones, E. G. & Powell, T. P. S. 1970*b* Electron microscopy of the somatic sensory cortex of the cat. II. The fine structure of layers I and II. *Phil. Trans. R. Soc. Lond. B* **257**, 13-21.
- Jones, E. G. & Powell, T. P. S. 1970*c* Electron microscopy of the somatic sensory cortex of the cat. III. The fine structure of layers III to VI. *Phil. Trans. R. Soc. Lond. B* **257**, 23-28.
- Kaiserman-Abramof, I. R. & Peters, A. 1972 Some aspects of the morphology of Betz cells in the cerebral cortex of the cat. *Brain Res.* **43**, 527-546.
- Le Vay, S. 1973 Synaptic patterns in the visual cortex of the cat and monkey. Electron microscopy of Golgi preparations. *J. comp. Neurol.* **150**, 53-86.
- Lorente de Nó, R. 1949 Cerebral cortex: architectonics, intracortical connections. In *Physiology of the Nervous system* by J. F. Fulton, pp. 274-301. Oxford University Press.
- Lund, J. S. & Lund, R. D. 1970 The termination of callosal fibres in the paravisceral cortex of the rat. *Brain Res.* **17**, 25-45.
- Marin-Padilla, M. 1969 Origin of the pericellular baskets of the human motor cortex: a Golgi study. *Brain Res.* **14**, 633-646.
- Marin-Padilla, M. 1970 Prenatal and early postnatal ontogenesis of the human motor cortex: a Golgi study. 2. The basket-pyramidal system. *Brain Res.* **23**, 185-191.
- Peters, A. 1971 Stellate cells of the rat parietal cortex. *J. comp. Neurol.* **141**, 345-374.

- Peters, A. & Kaiserman-Abramof, I. R. 1970 The small pyramidal neuron of rat cerebral cortex. The perikaryon, dendrites and spines. *Am. J. Anat.* **127**, 321–356.
- Rockel, A. J., Hiorns, R. W. & Powell, T. P. S. 1974 Numbers of neurons through full depth of neocortex. *J. Anat.* **118**, 371.
- Sloper, J. J. 1971 Dendro-dendritic synapses in the primate motor cortex. *Brain Res.* **34**, 186–192.
- Sloper, J. J. 1972 Gap junctions between dendrites in the primate neocortex. *Brain Res.* **44**, 641–646.
- Sloper, J. J. 1973a An electron microscopic study of the neurons of the primate motor and somatic sensory cortices. *J. Neurocytol.* **2**, 351–359.
- Sloper, J. J. 1973b An electron microscope study of the termination of afferent connections to the primate motor cortex. *J. Neurocytol.* **2**, 361–368.
- Sloper, J. J. 1973c The relationship of subsurface cisternae and cisternal organs to symmetrical axon terminals in the primate sensori-motor cortex. *Brain Res.* **58**, 478–483.
- Sloper, J. J. 1977 A neurohistological study of the sensori-motor cortex. D.Phil. thesis, University of Oxford.
- Sloper, J. J. & Powell, T. P. S. 1979a Ultrastructural features of the sensori-motor cortex of the primate. *Phil. Trans. R. Soc. Lond. B* **285**, 123–139.
- Sloper, J. J. & Powell, T. P. S. 1979b An experimental electron microscopic study of afferent connections to the primate motor and somatic sensory cortices. *Phil. Trans. R. Soc. Lond. B* **285**, 199–226.
- Szentágothai, J. 1964 The use of degeneration methods in investigation of short neuronal connections. *Prog. Brain Res.* **14**, 1–30.
- Szentágothai, J. 1969 Architecture of the cerebral cortex. In *Basic mechanisms of the epilepsies* (ed. H. H. Jasper, A. A. Ward & A. Pope), pp. 13–28. London: Churchill.
- Szentágothai, J. 1973 Synaptology of the visual cortex. In *Handbook of sensory physiology*, vol. VII/3 (ed. R. Jung), pp. 269–324. Berlin: Springer.
- Tömböl, T. 1974 An electron microscopic study of the neurons of the visual cortex. *J. Neurocytol.* **3**, 525–531.
- Valverde, F. 1971 Short axon neuronal subsystems in the visual cortex of the monkey. *Internat. J. Neurosci.* **1**, 181–197.

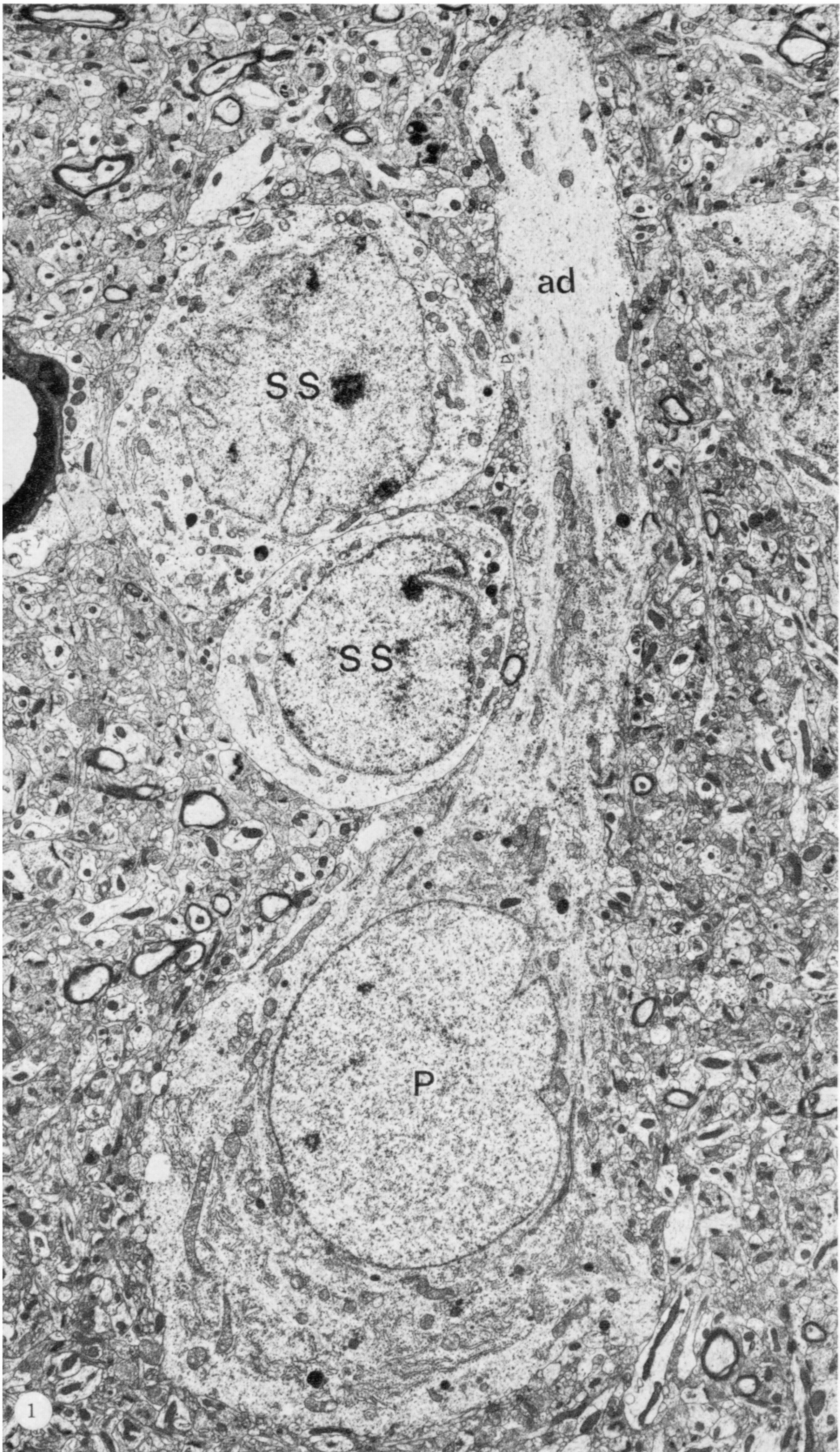


FIGURE 1. A pyramidal (P) and two small stellate neurons (SS) from layer II of the motor cortex. Note the more darkly staining nuclei with clumped chromatin of the small stellate cells and their paler cytoplasm containing few organelles. ad, Apical dendrite. (Magn. $\times 4500$.)

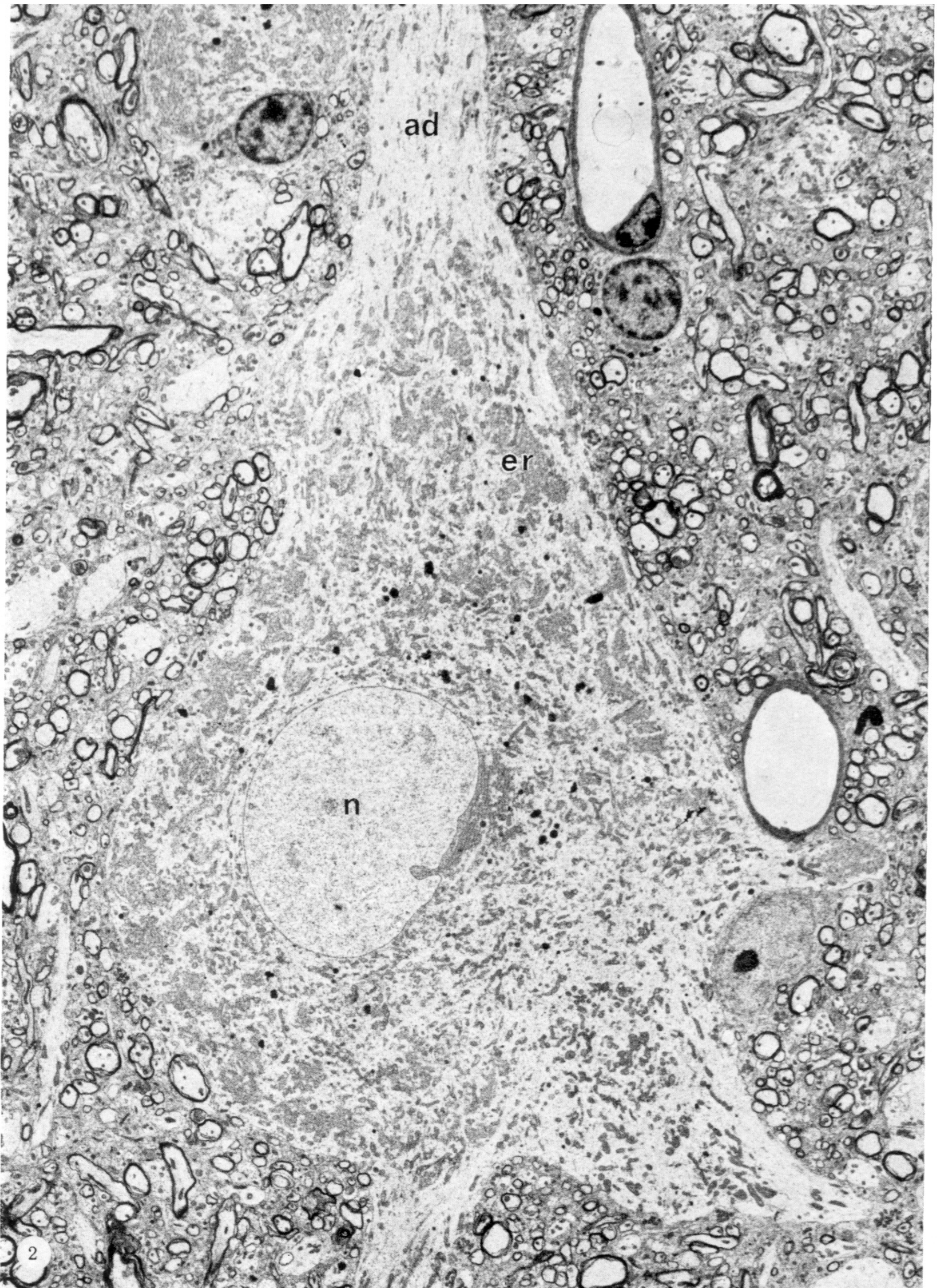
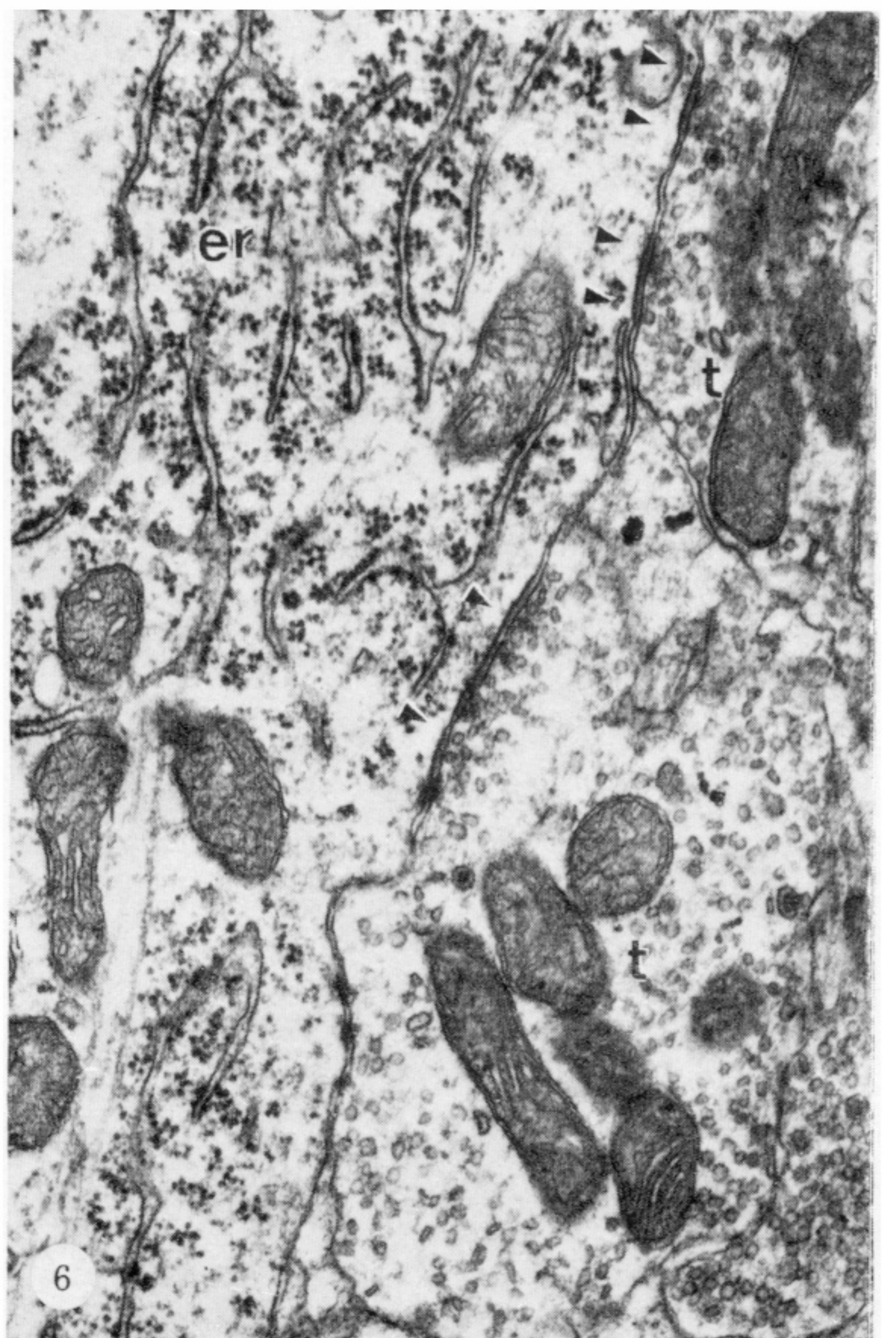
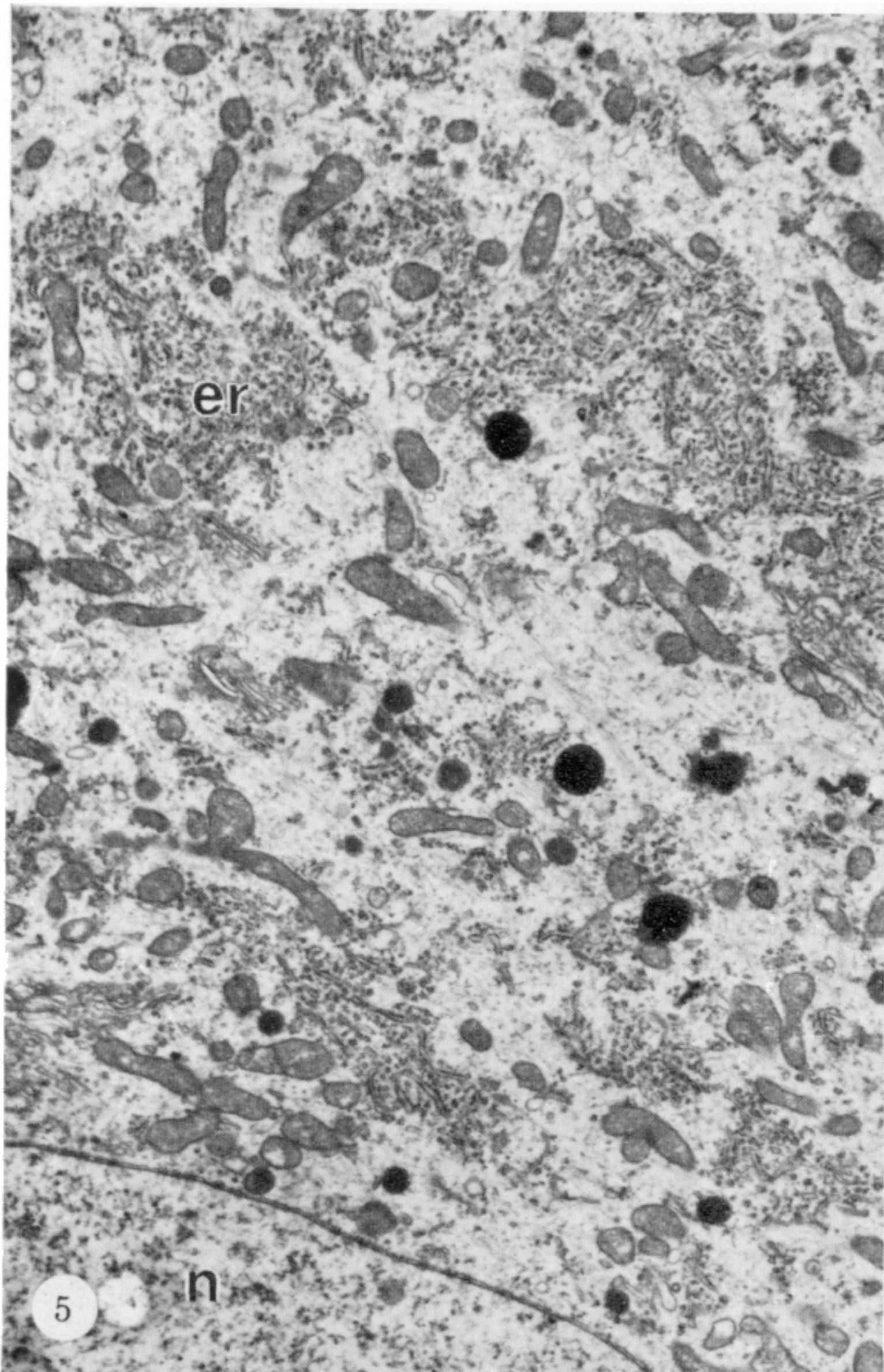
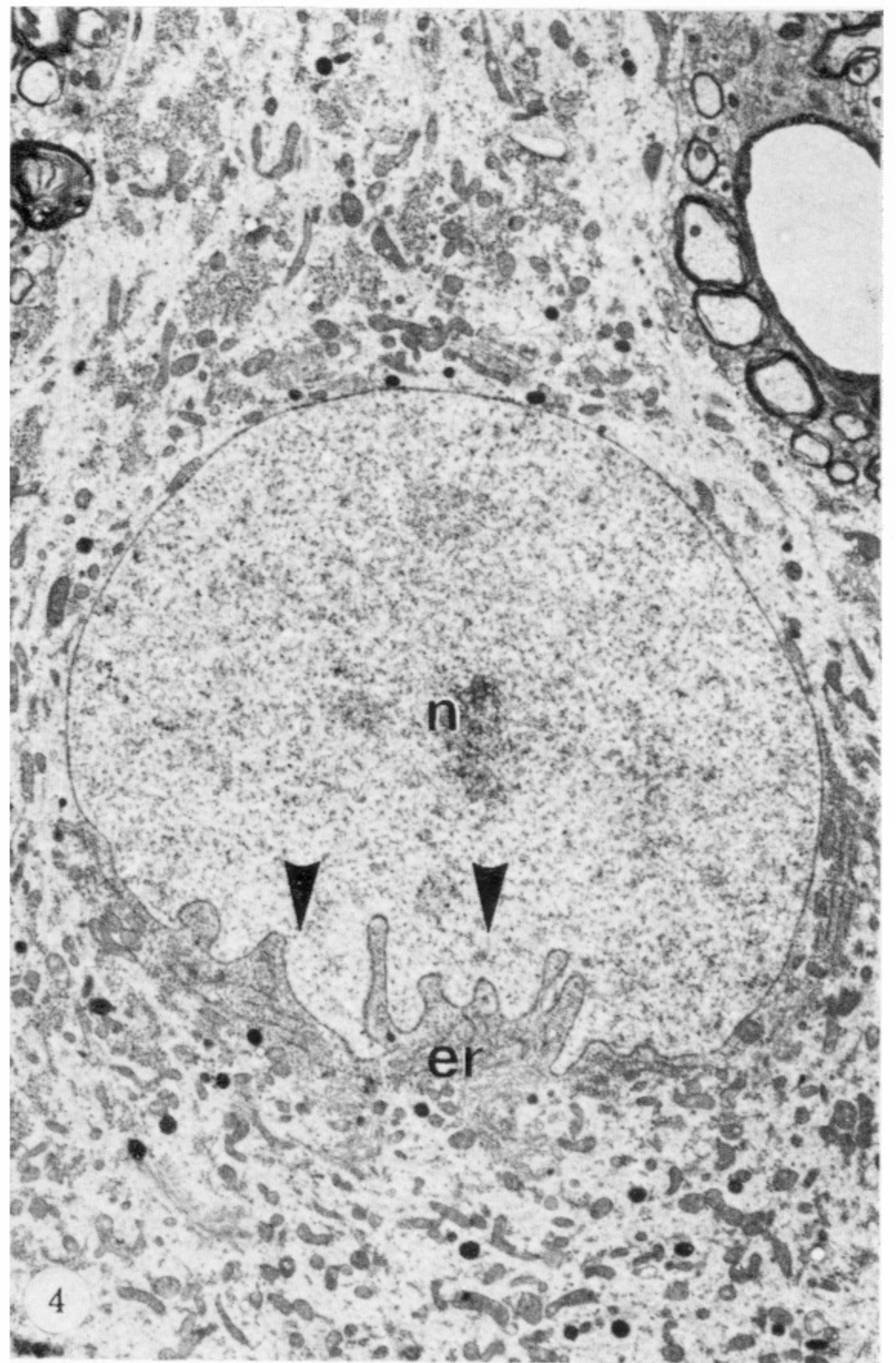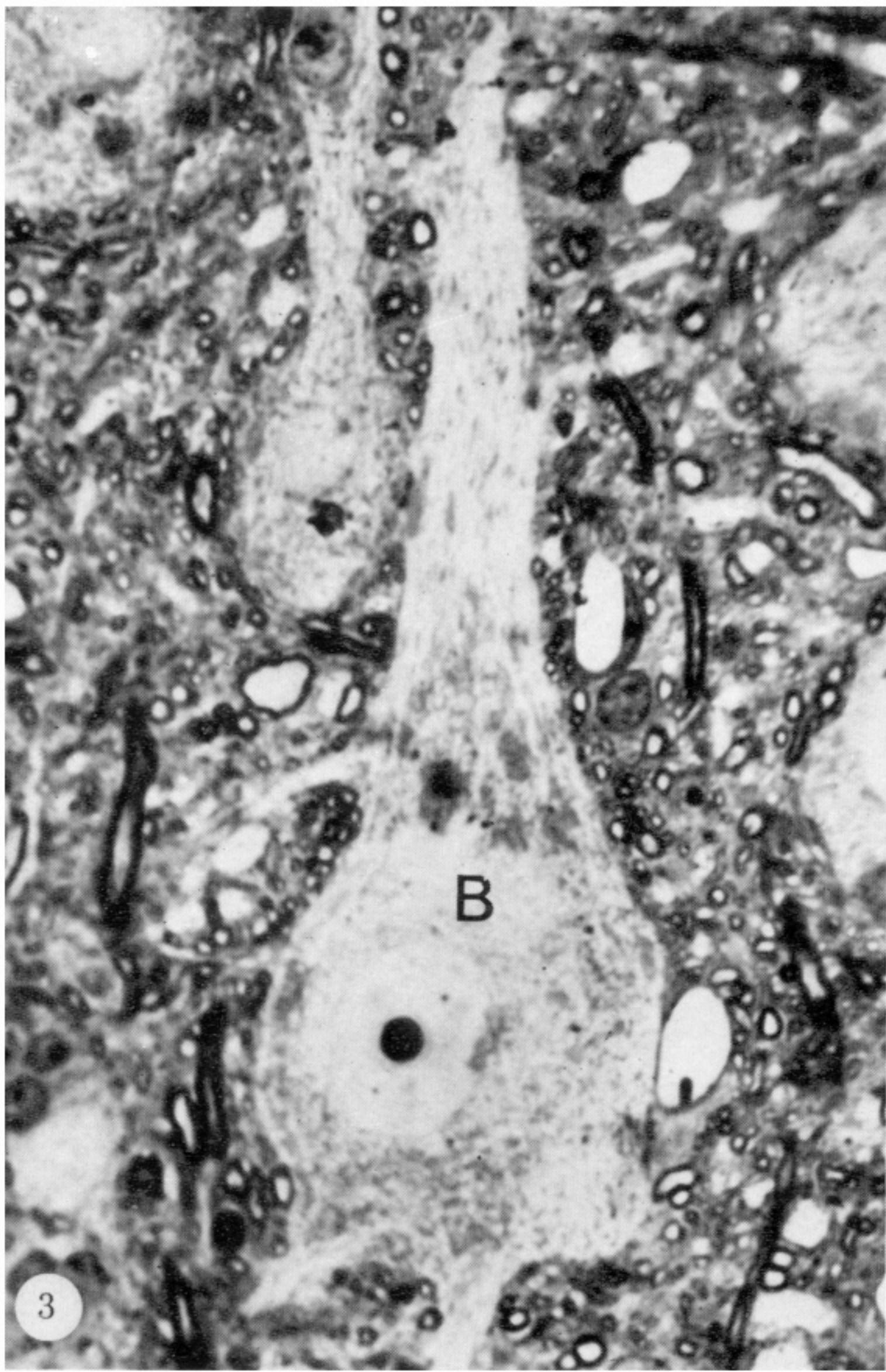


FIGURE 2. For description see opposite.



FIGURES 3-6. For description see opposite.

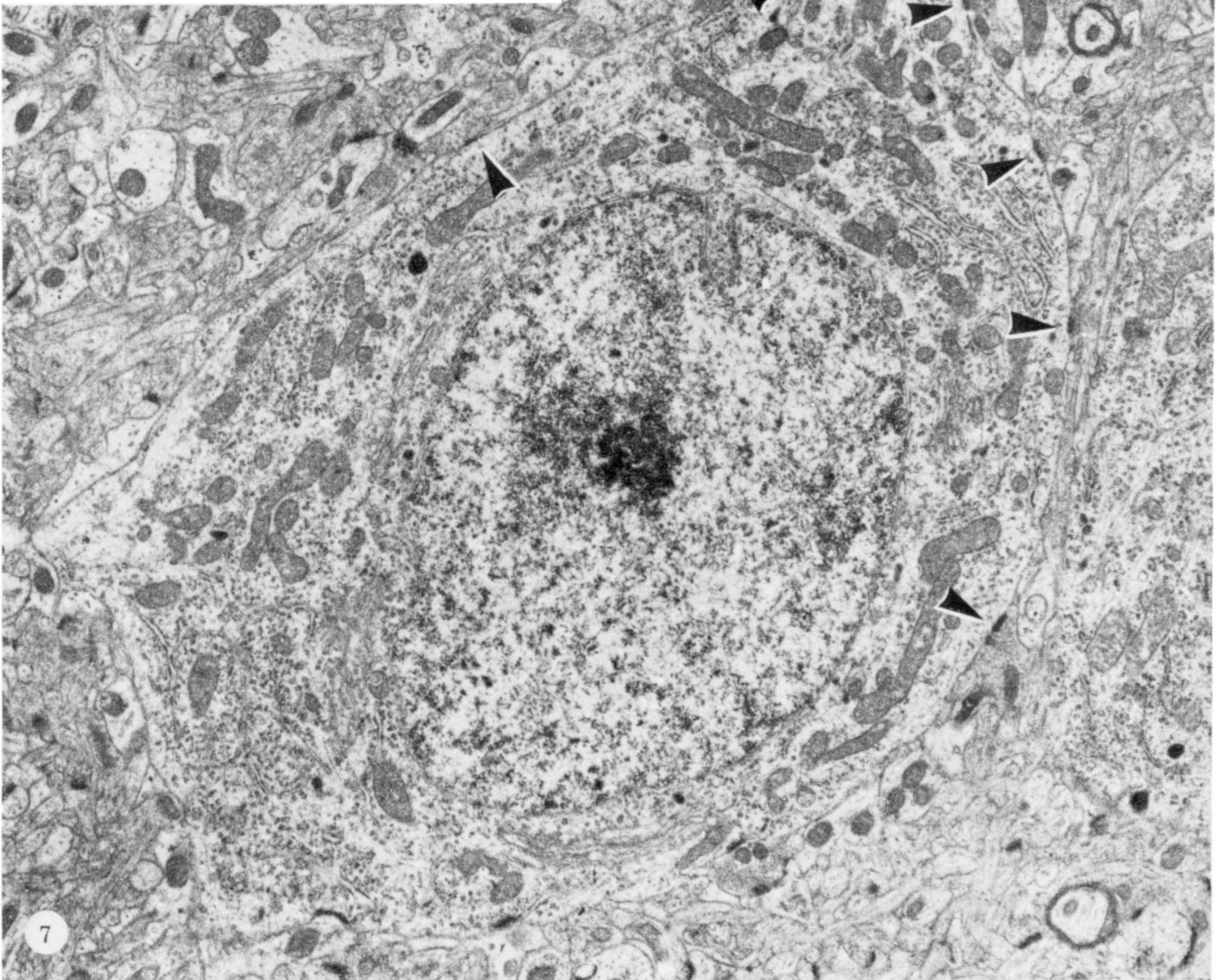
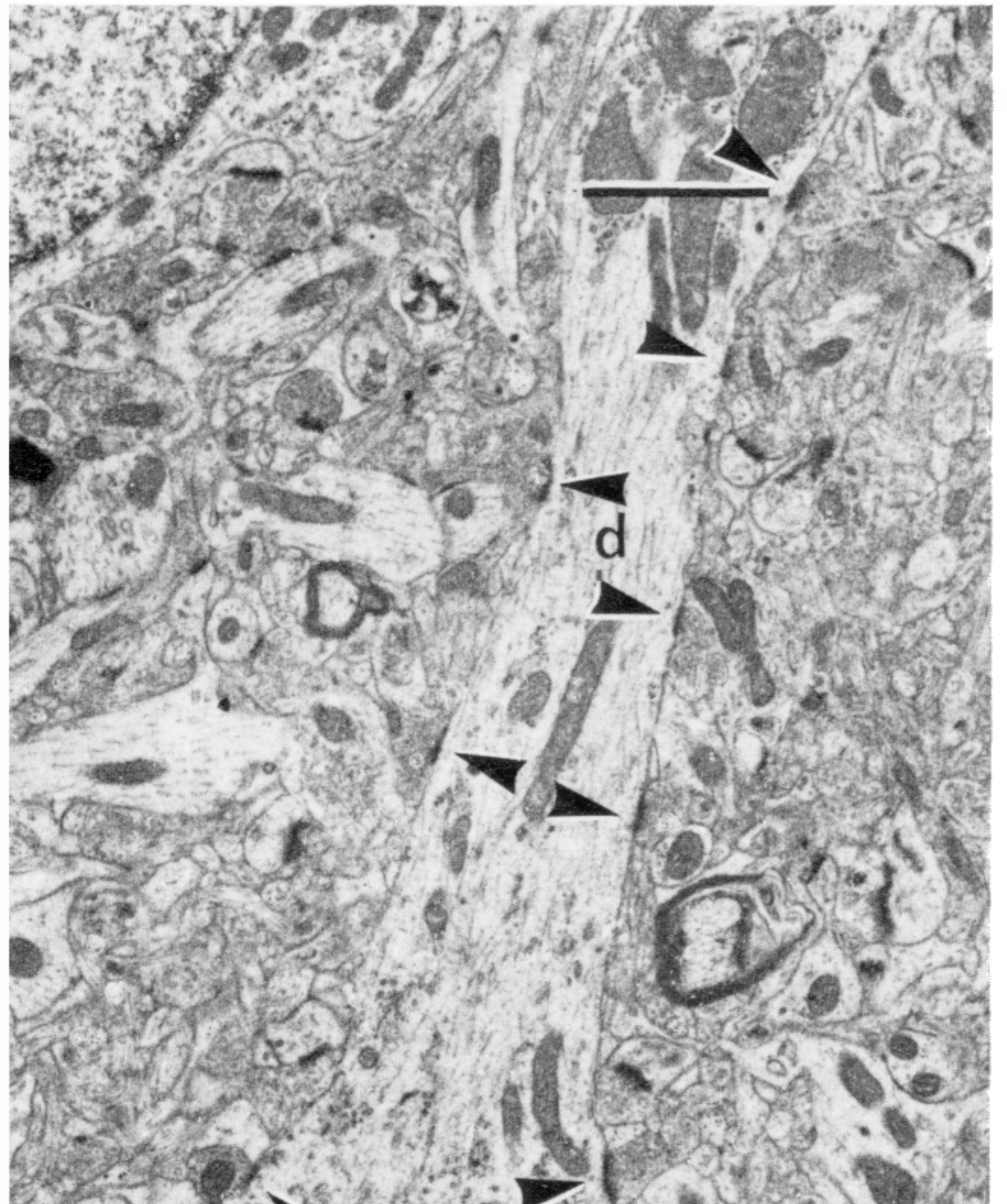
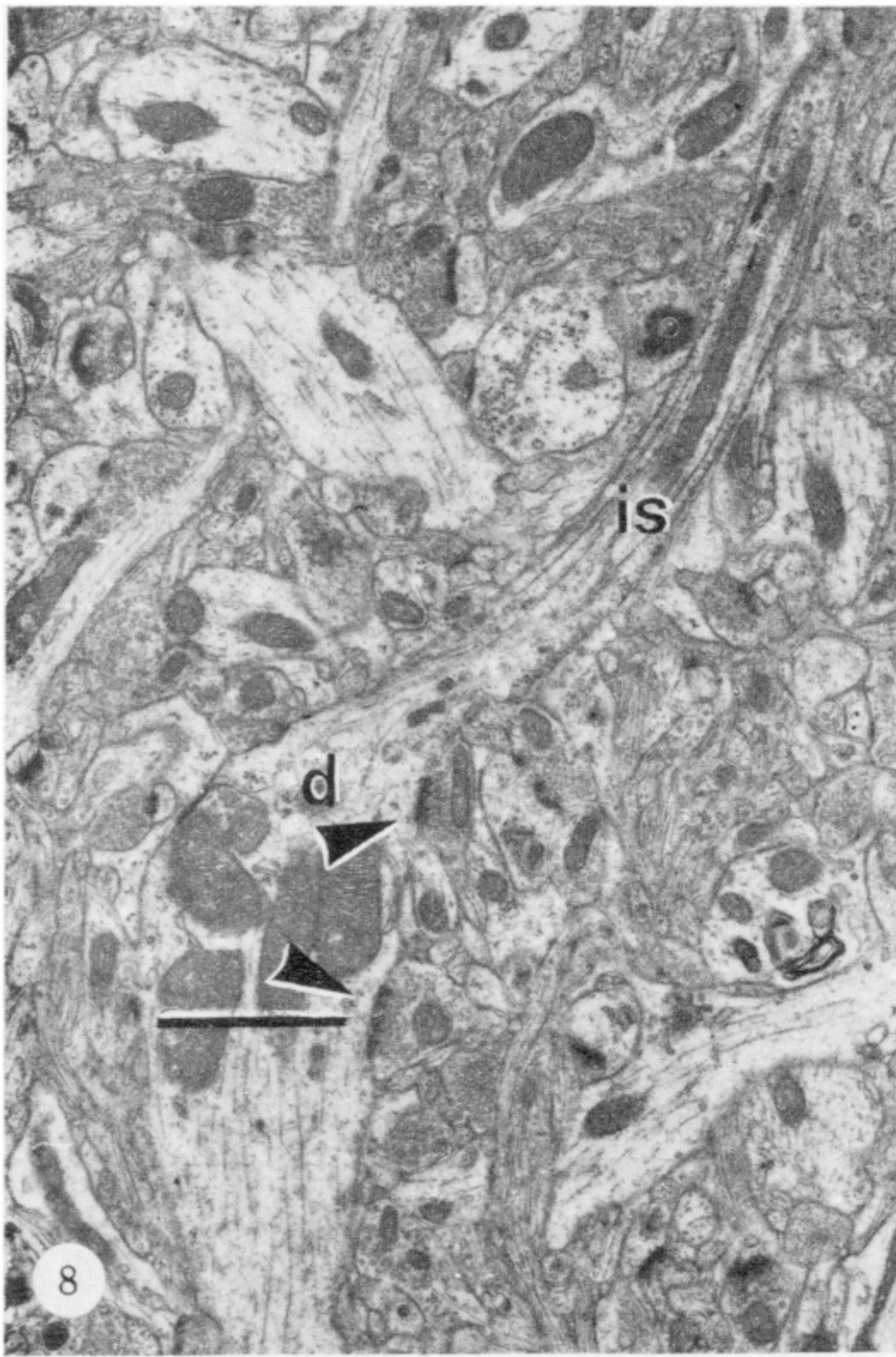
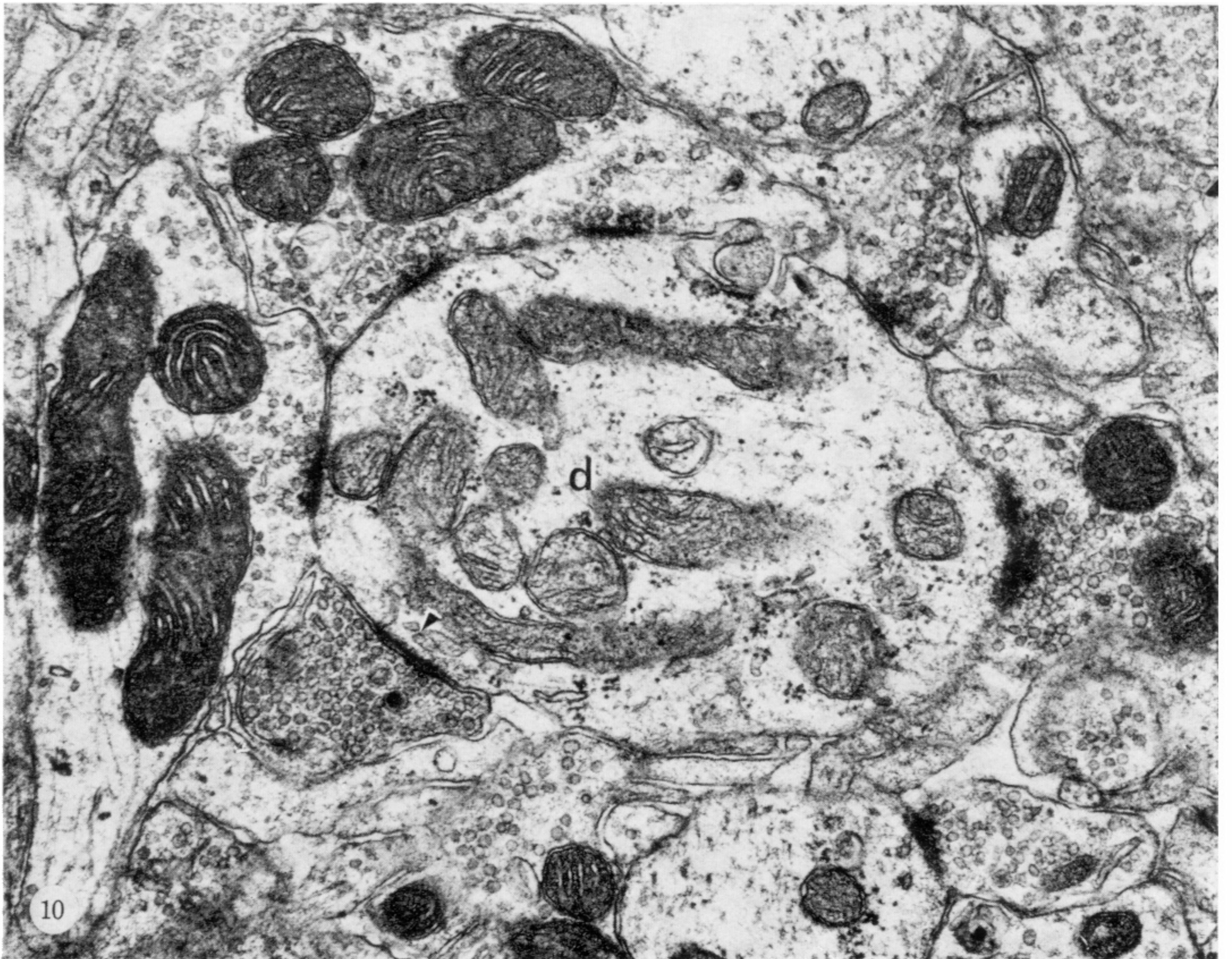
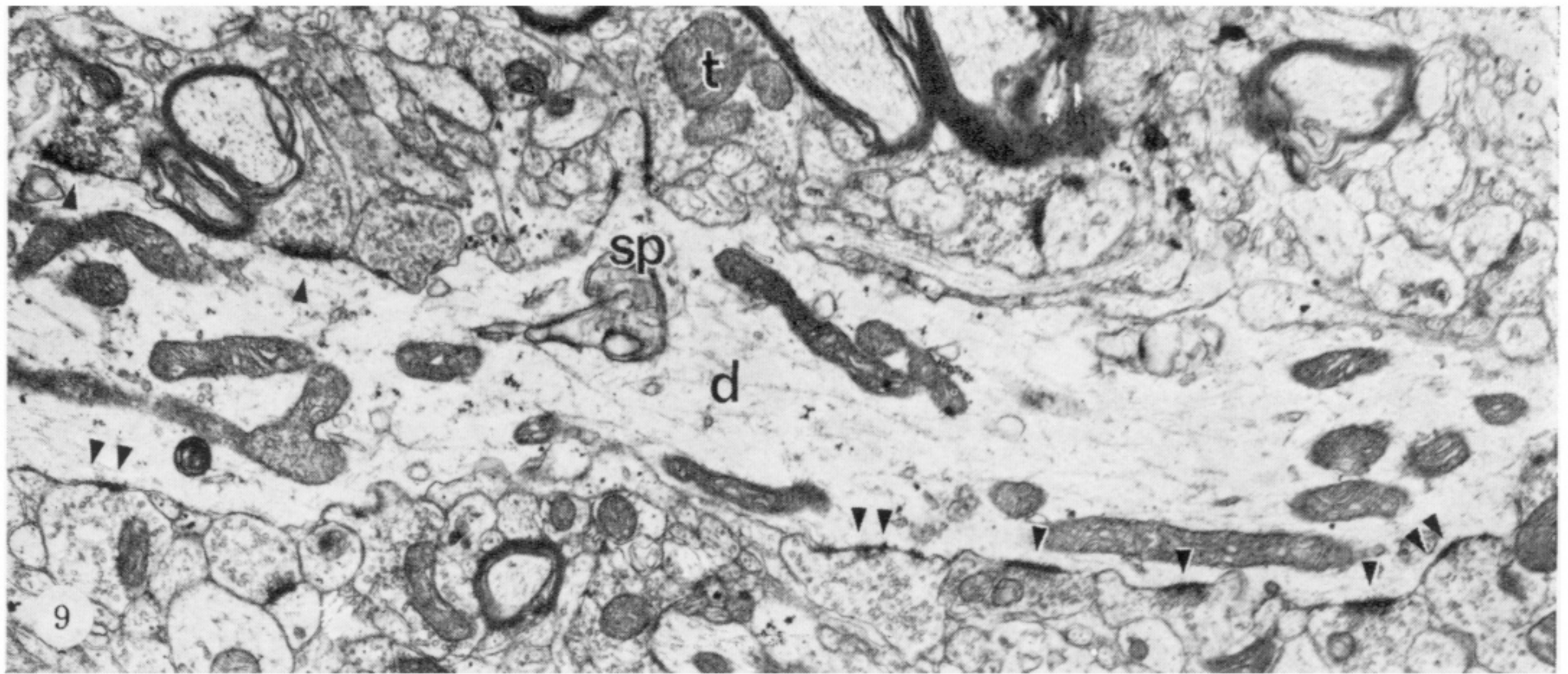
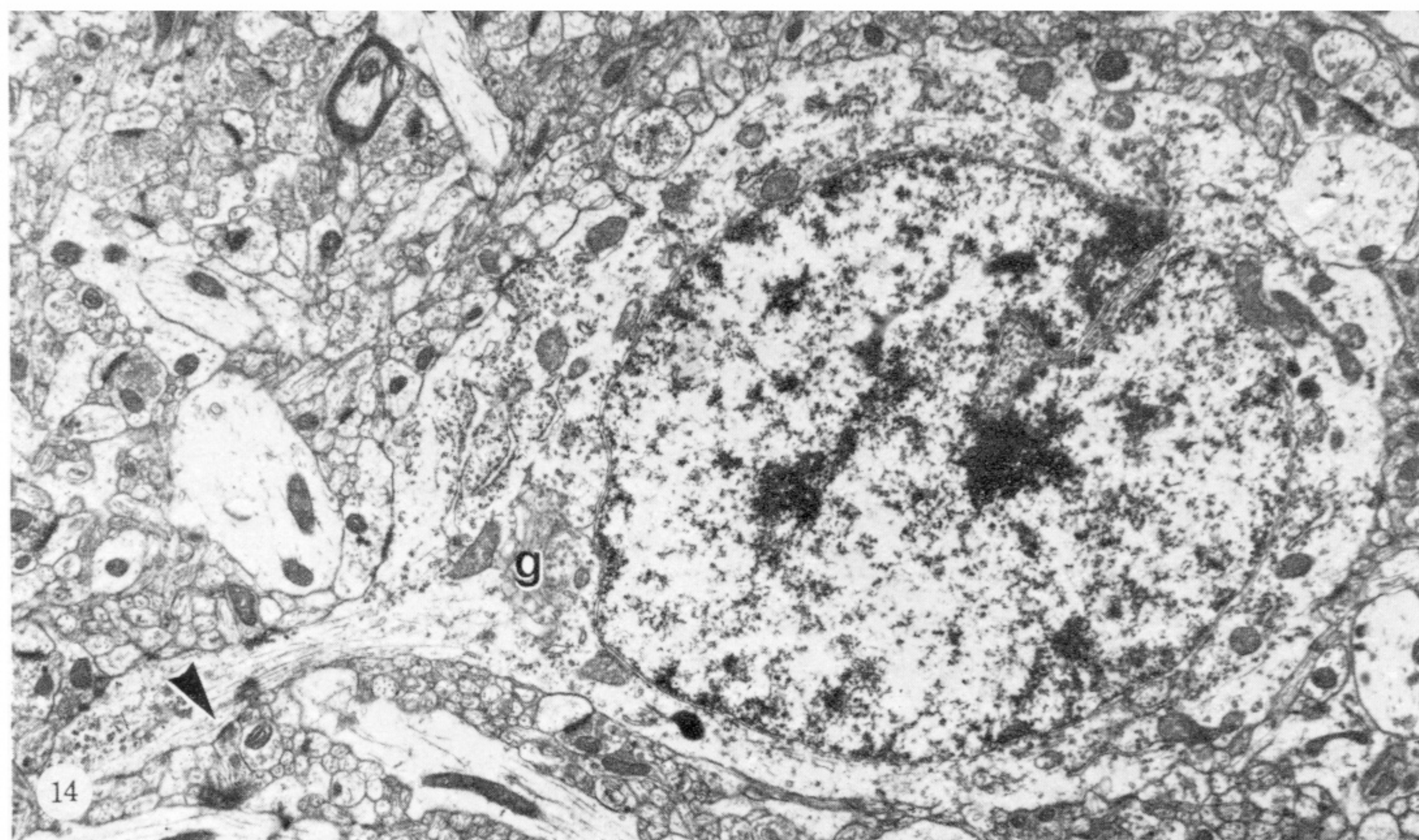
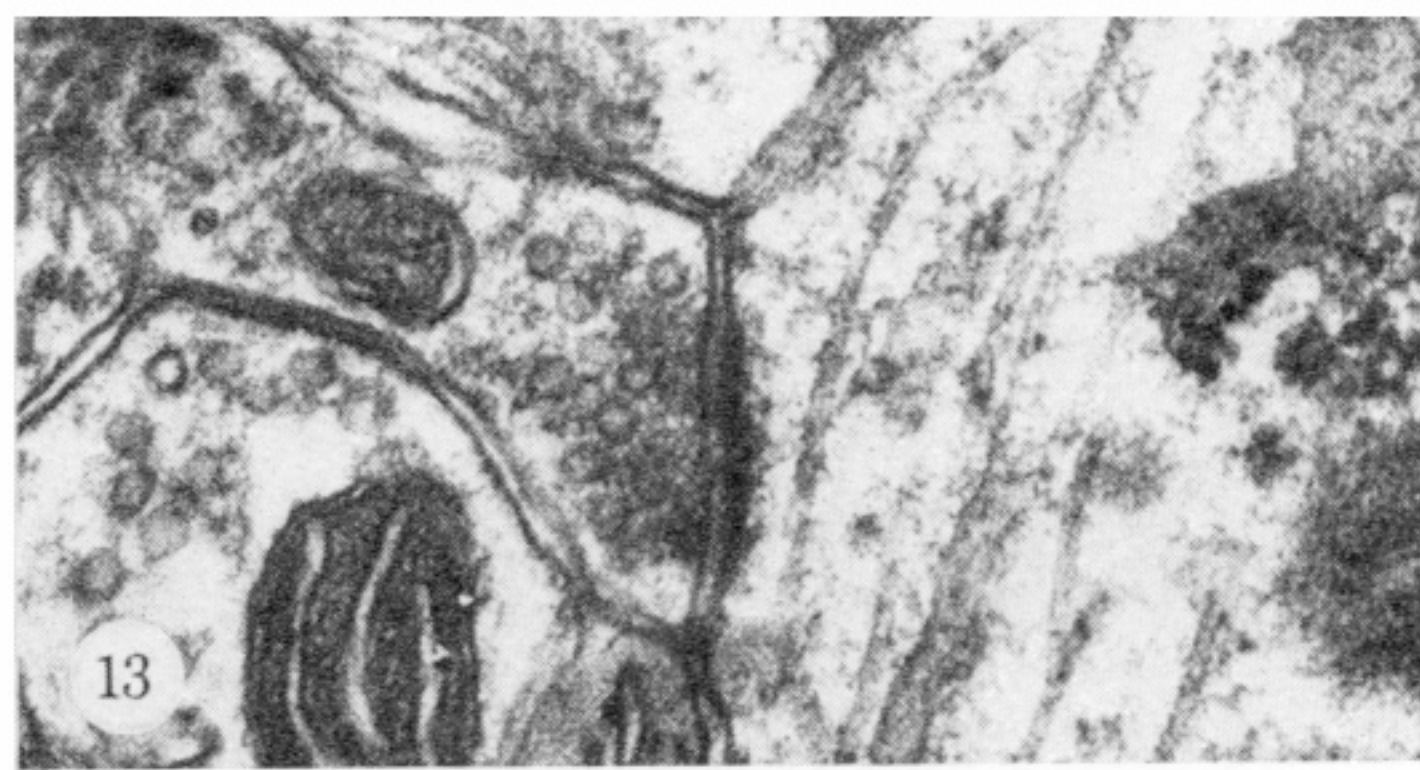
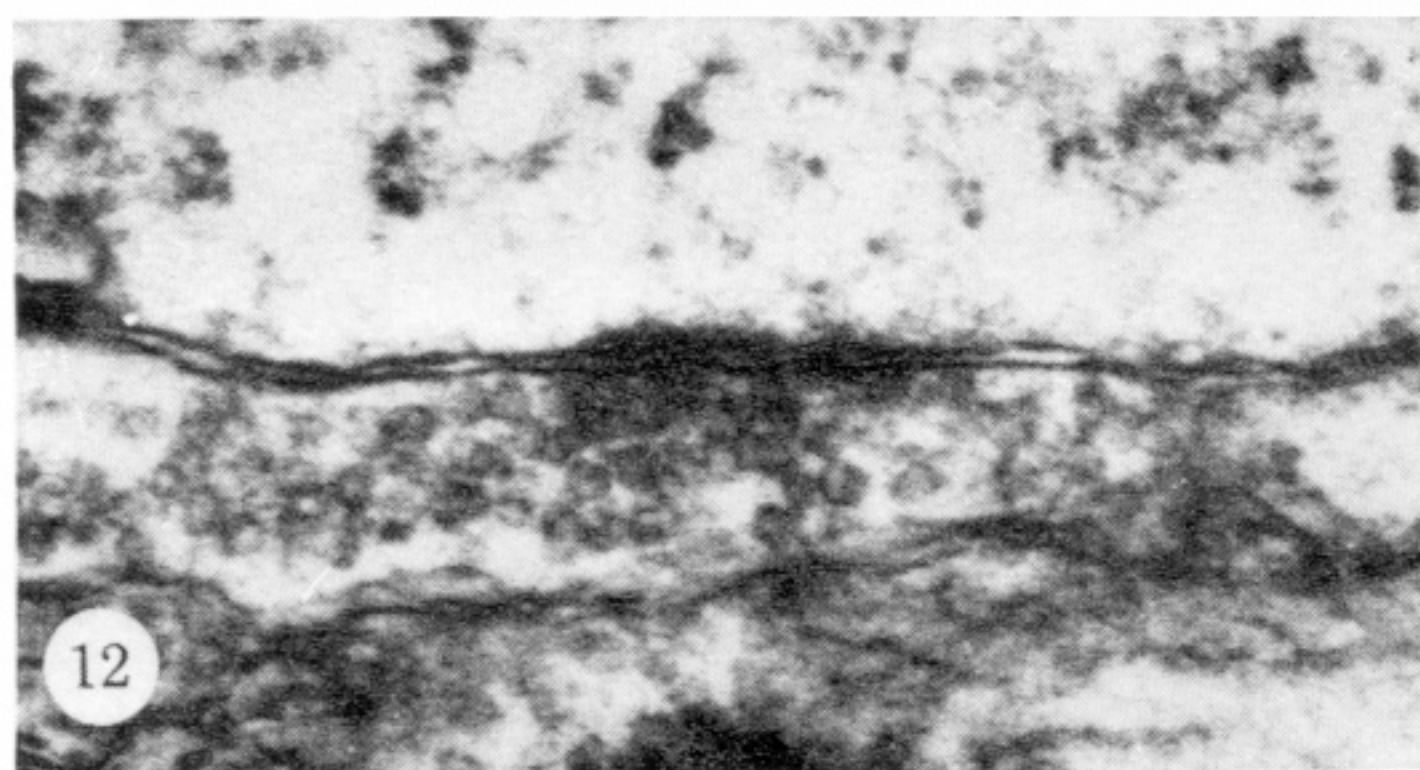
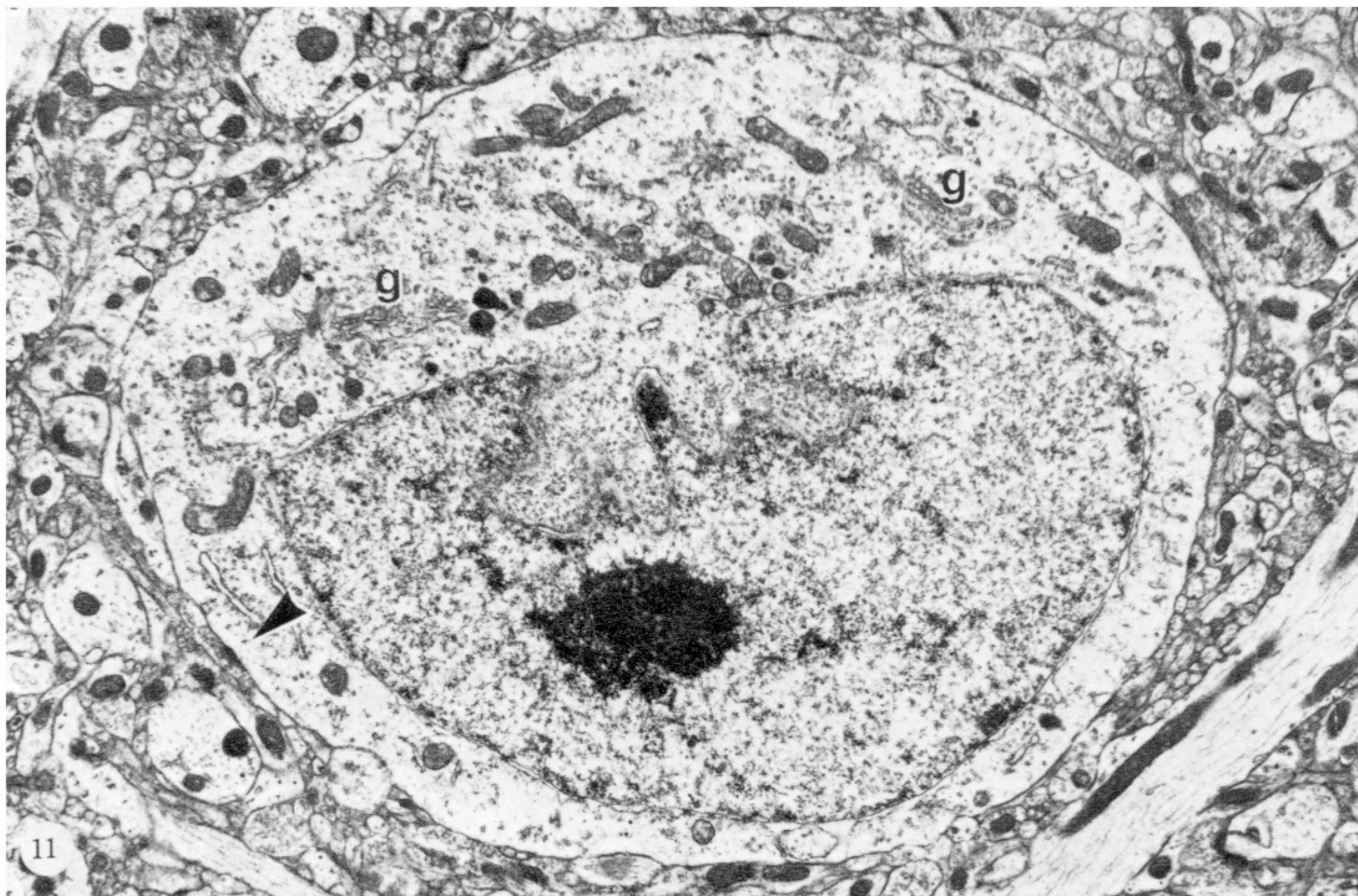


FIGURE 7. Large stellate neuron from layer III of the motor cortex. Note the abundant cytoplasm full of organelles. The cell soma and dendrite (d) receive a considerable number of synapses (large arrowheads) although not as many as in many examples. (Magn. $\times 11\,000$.)

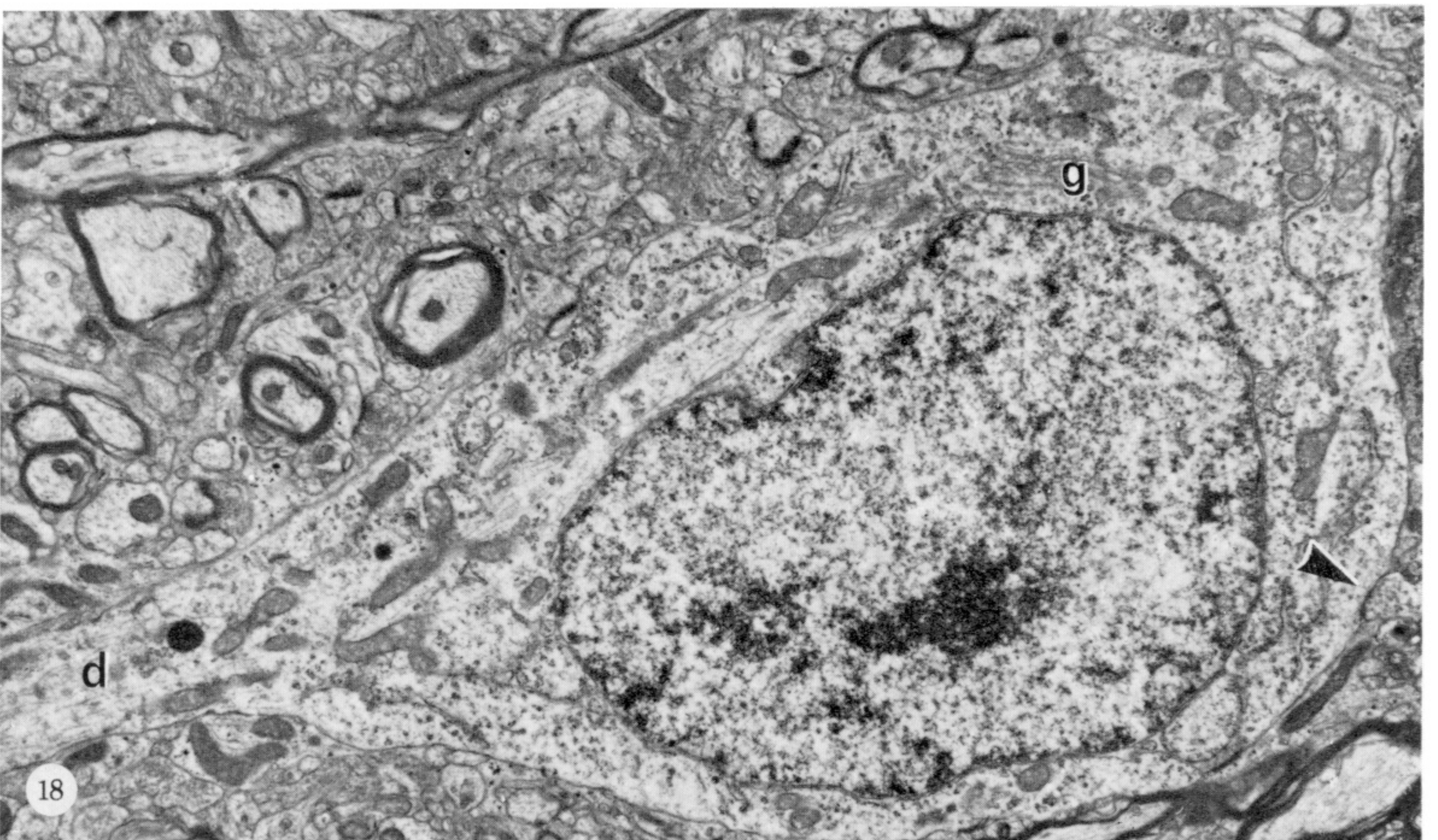
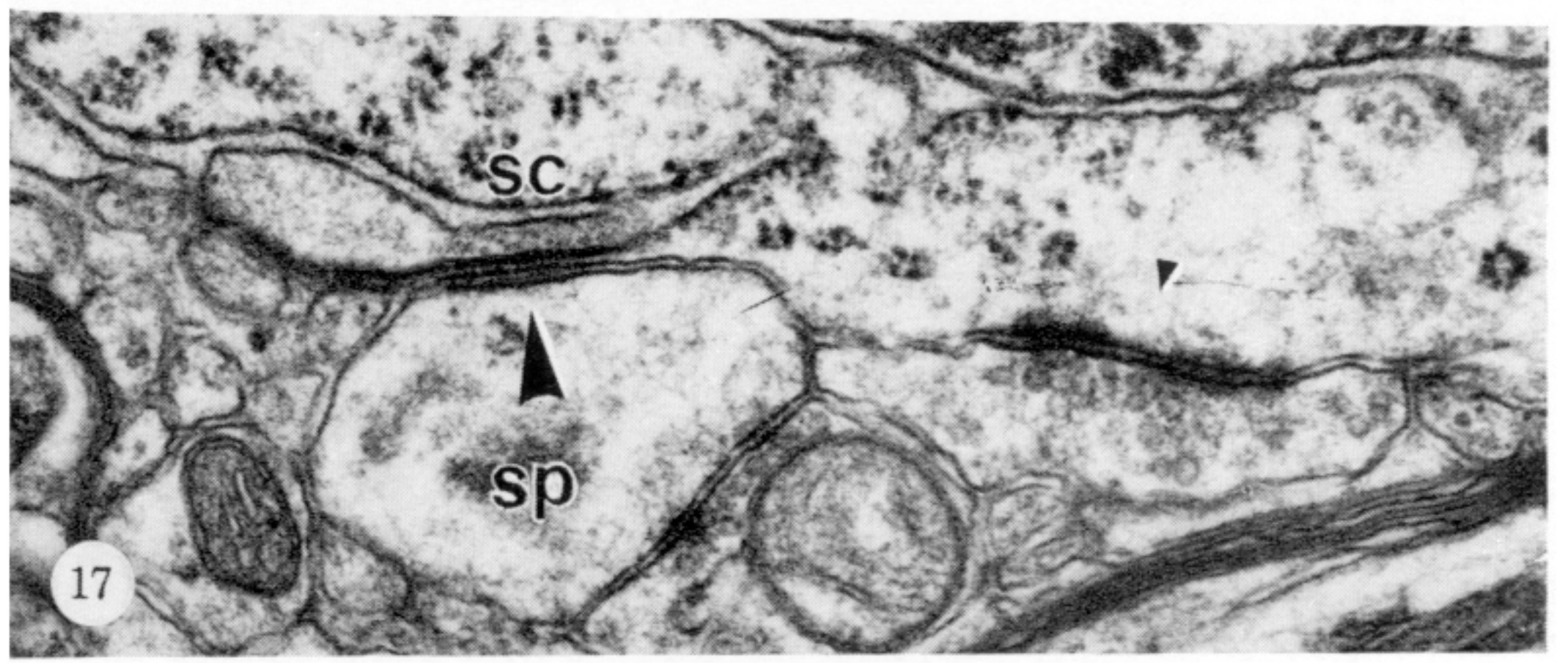
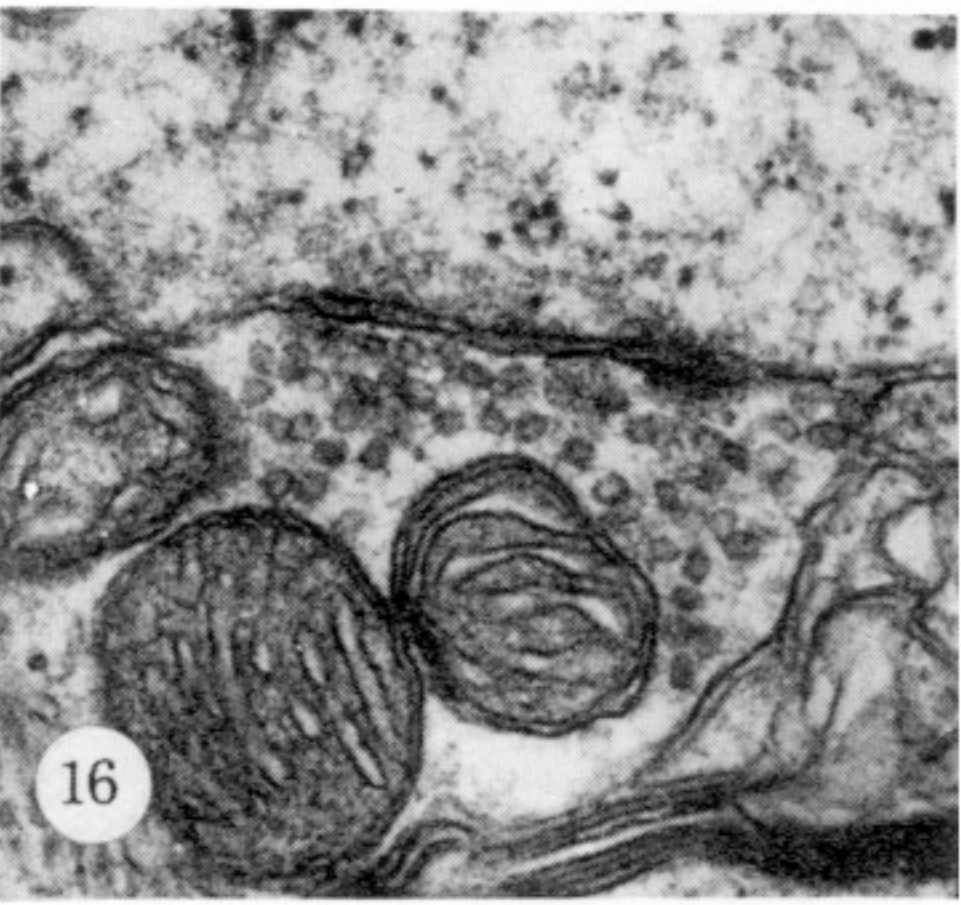
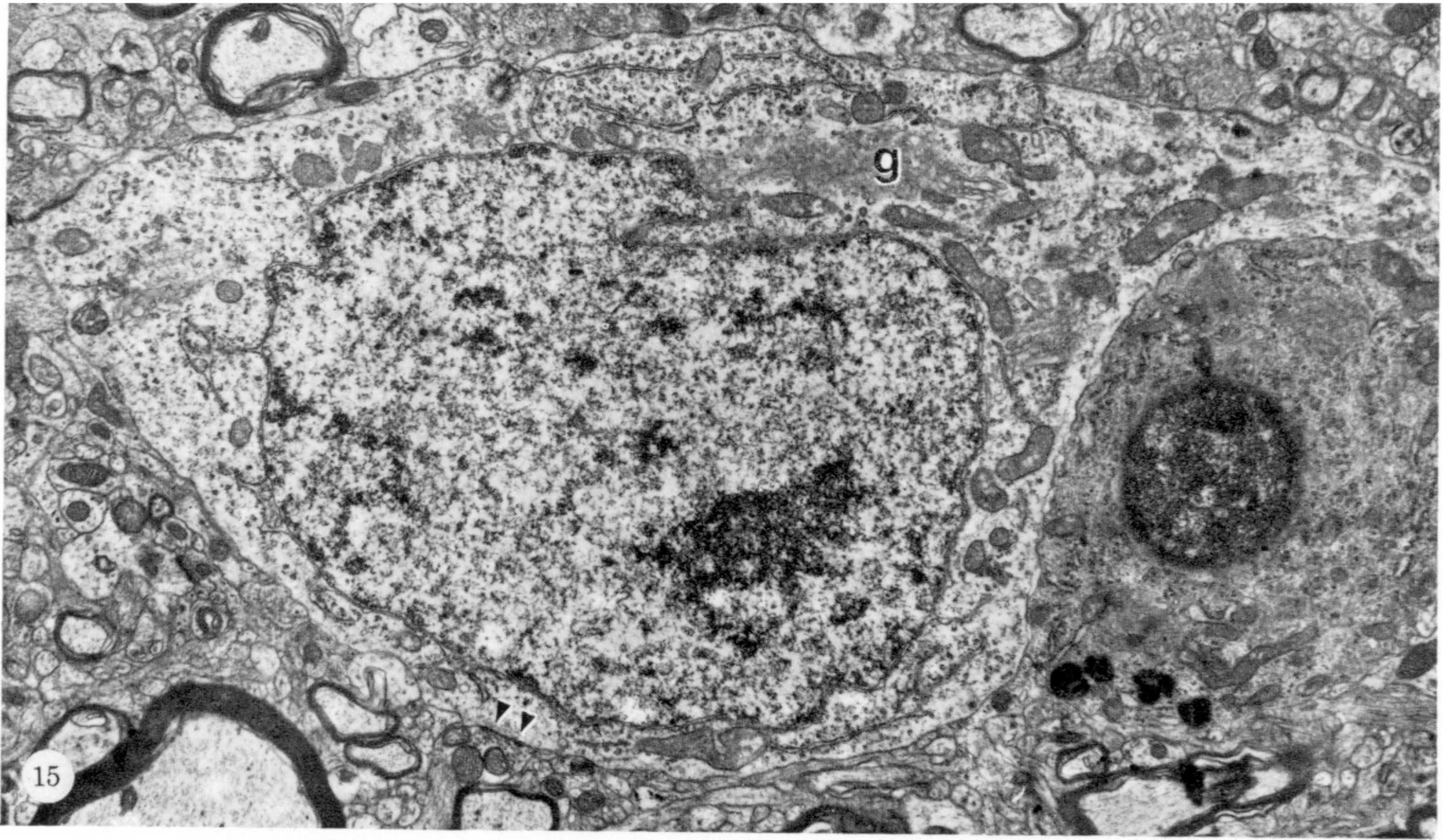
FIGURE 8. The origin of the initial segment (is) of the large stellate cell of figure 7 from the continuation of its dendrite (d) in a close serial section. The black bar occupies an equivalent position on both of the illustrations. Note the curvature of the first part of the initial segment. (Magn. $\times 11\,000$.)



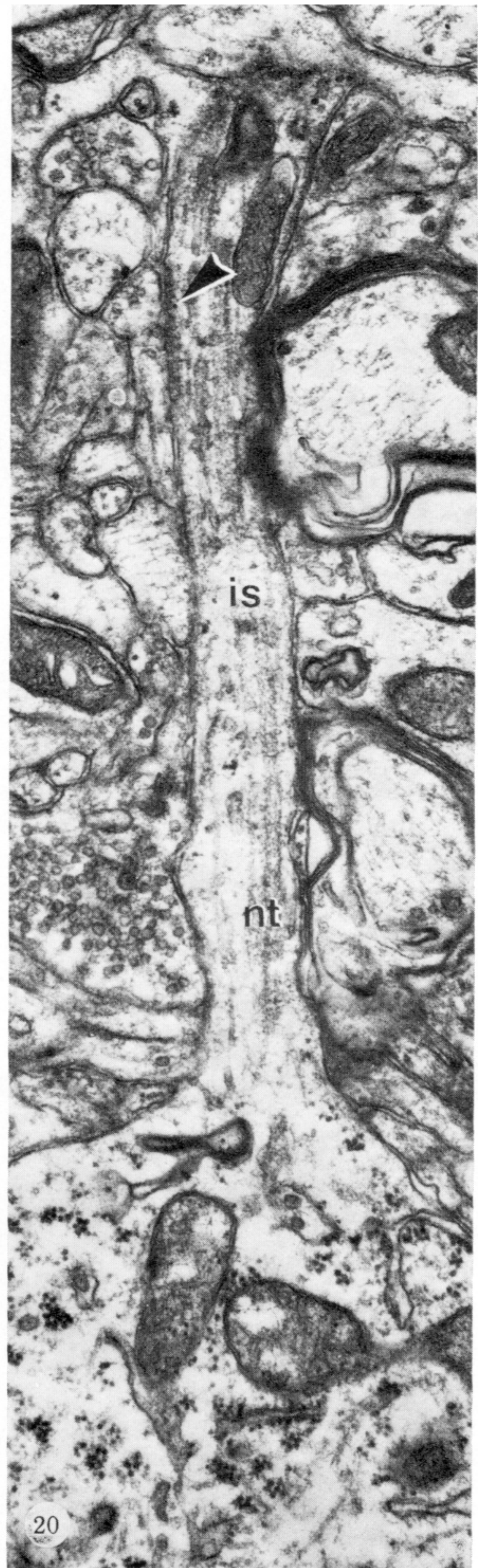
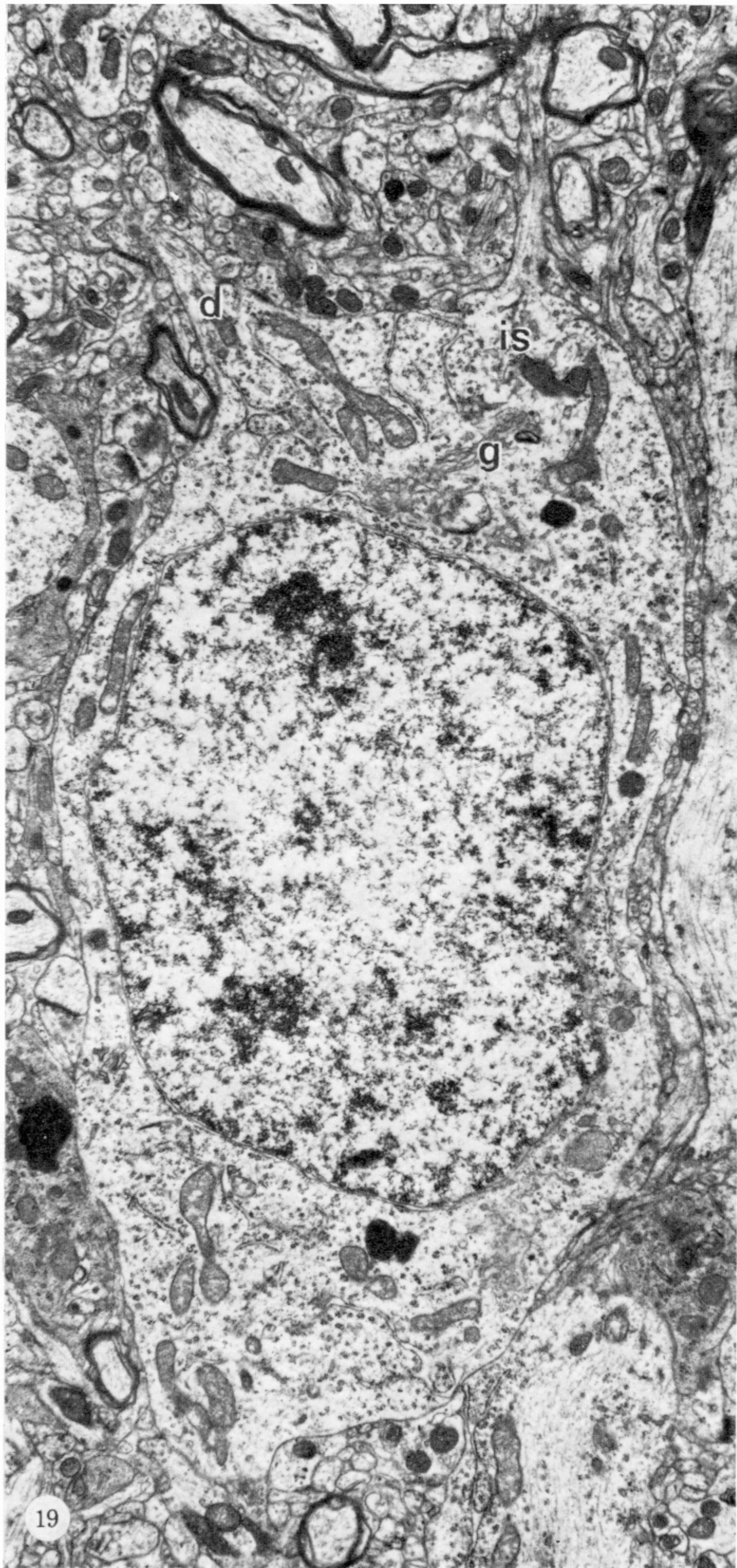
FIGURES 9 and 10. For description see opposite.



FIGURES 11-14. For description see opposite.



FIGURES 15-18. For description see opposite.



FIGURES 19 and 20. For description see opposite.

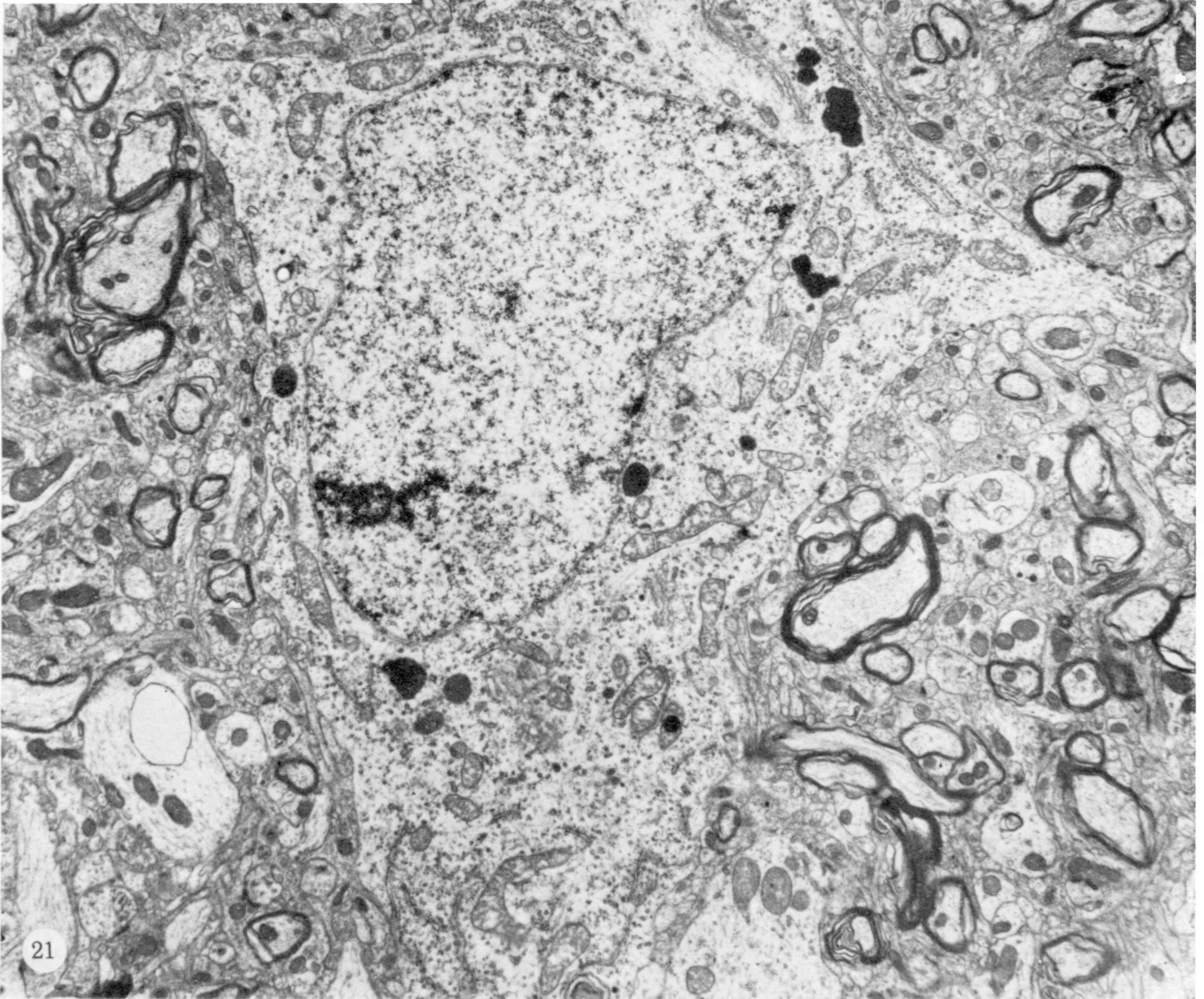
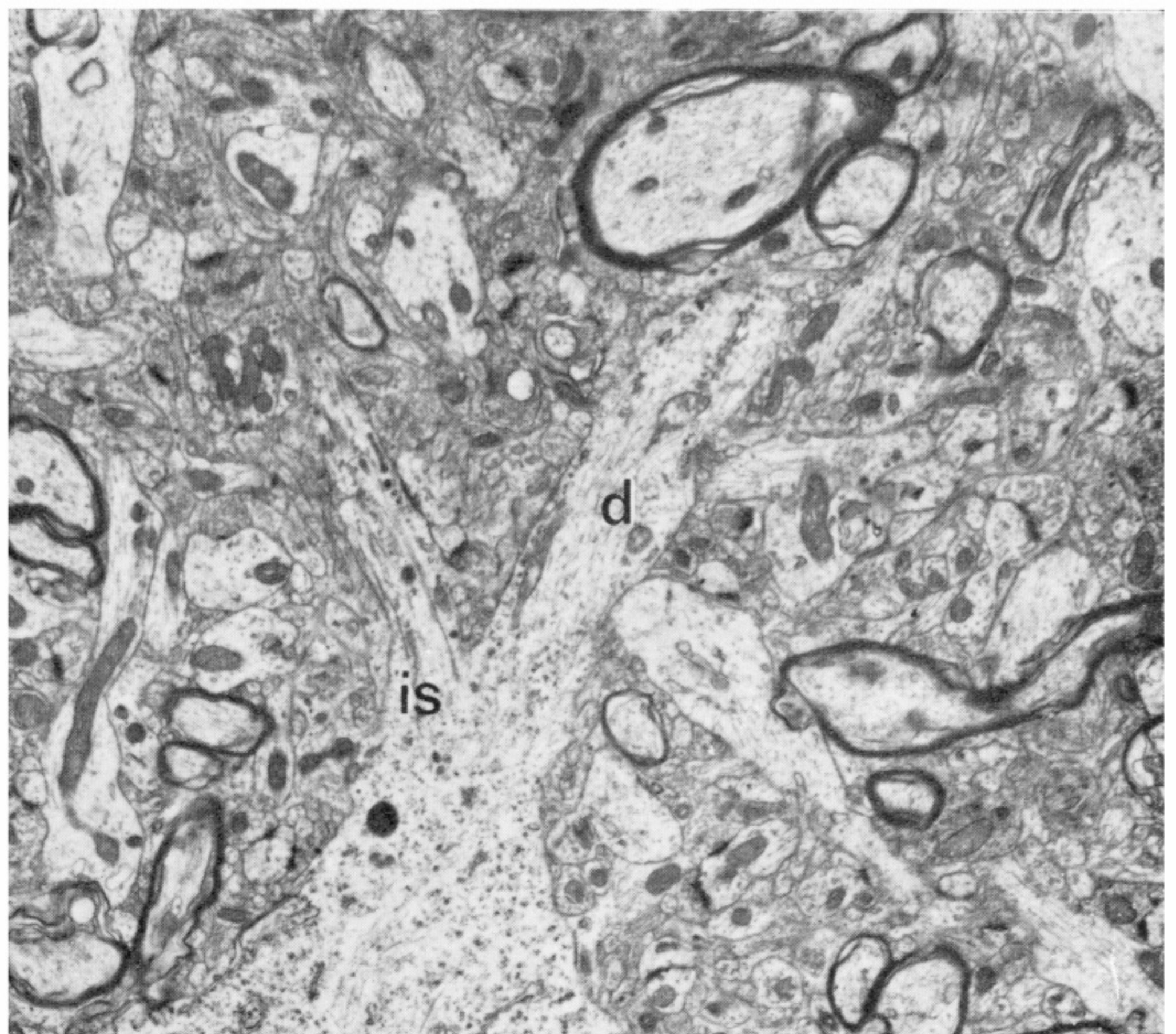
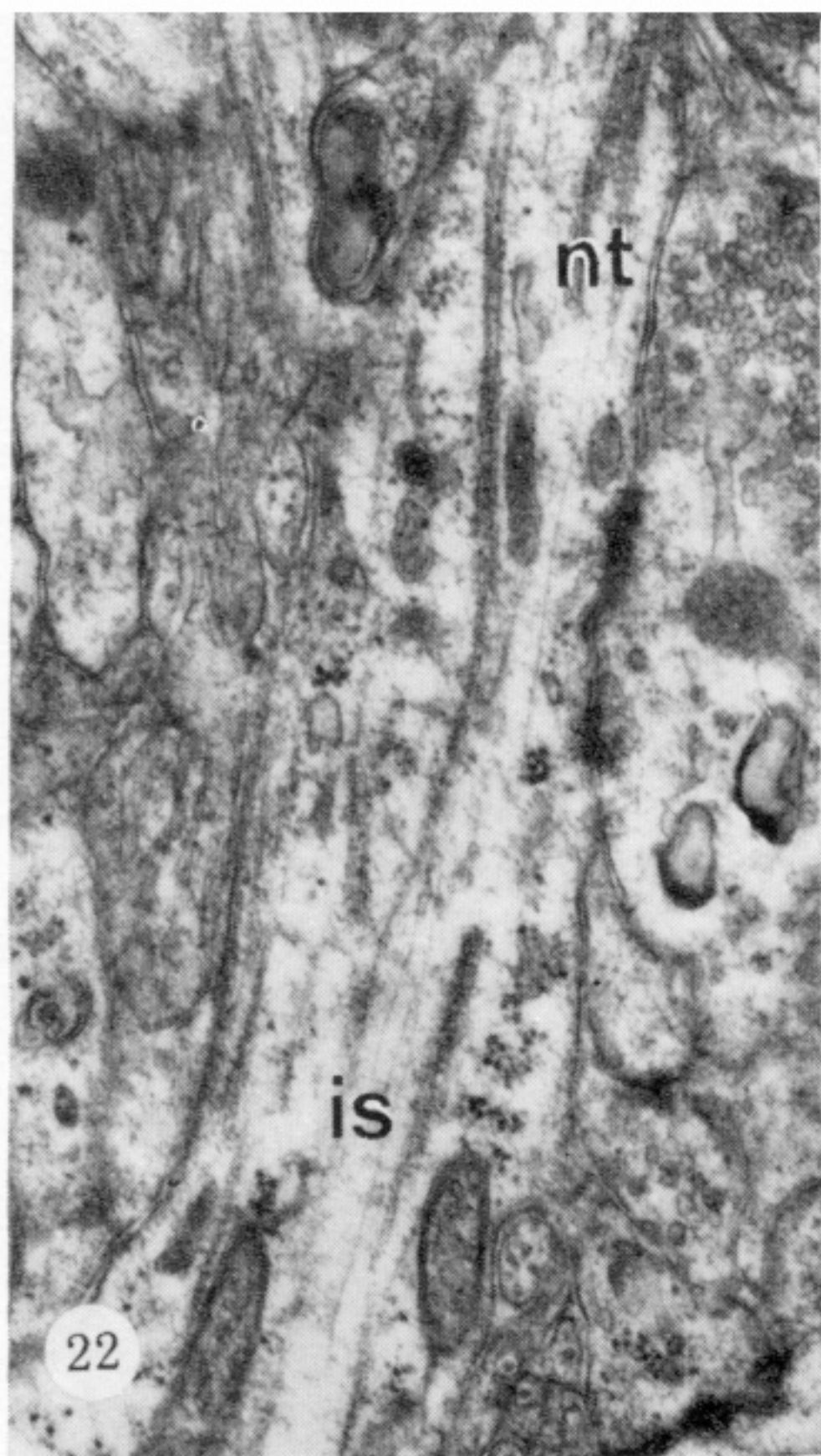


FIGURE 21. Neuron from layer V of the motor cortex. This is an example of an unusual type of neuron from layer V which is large, receives few synapses and has an axon initial segment (is) directed towards the cortical surface, and is therefore probably a Martinotti cell. The initial segment arises from the root of the dendrite (d). (Magn. $\times 6300$.)

FIGURE 22. Initial segment of the neuron of figure 21 at a greater magnification and in the next serial section. Note the bundle of neurotubules (nt). (Magn. $\times 19000$.)